



King's Research Portal

DOI:

[10.1097/WNR.0000000000000974](https://doi.org/10.1097/WNR.0000000000000974)

Document Version

Peer reviewed version

[Link to publication record in King's Research Portal](#)

Citation for published version (APA):

James, A., von Oertzen, T. J., Norbury, R., Huppertz, H-J., & Brandt, K. R. (2018). Left entorhinal cortex and object recognition. *Neuroreport*, 29(5), 363-367. <https://doi.org/10.1097/WNR.0000000000000974>

Citing this paper

Please note that where the full-text provided on King's Research Portal is the Author Accepted Manuscript or Post-Print version this may differ from the final Published version. If citing, it is advised that you check and use the publisher's definitive version for pagination, volume/issue, and date of publication details. And where the final published version is provided on the Research Portal, if citing you are again advised to check the publisher's website for any subsequent corrections.

General rights

Copyright and moral rights for the publications made accessible in the Research Portal are retained by the authors and/or other copyright owners and it is a condition of accessing publications that users recognize and abide by the legal requirements associated with these rights.

- Users may download and print one copy of any publication from the Research Portal for the purpose of private study or research.
- You may not further distribute the material or use it for any profit-making activity or commercial gain
- You may freely distribute the URL identifying the publication in the Research Portal

Take down policy

If you believe that this document breaches copyright please contact librarypure@kcl.ac.uk providing details, and we will remove access to the work immediately and investigate your claim.

This is a non-final version of an article published in final form in “James, A., von Oertzen, T. J., Norbury, R., Huppertz, H. J., & Brandt, K. R. (2018). Left entorhinal cortex and object recognition. *Neuroreport*, 29(5), 363-367.”

THIS DIFFERS FROM THE FINAL PUBLISHED ARTICLE, SO PLEASE REFER TO THAT ONE IF YOU WISH TO CITE THIS PAPER.

Neuroreport can be accessed online via this website address:

<https://journals.lww.com/neuroreport/>

This is the final peer-reviewed manuscript, embargoed until 21st March 2019.

1 **Left entorhinal cortex and object recognition** (*Running Head*)

2 Adele **James**^a

3 Tim J. **von Oertzen**^{b, c}

4 Ray **Norbury**^a

5 Hans-Juergen **Huppertz**^d

6 Karen R. **Brandt**^a

7

8 ^aDepartment of Psychology, Whitelands College, University of Roehampton, London, SW15

9 4JD, United Kingdom

10 ^b Atkinson Morley Neuroscience Centre, St. George's Hospital, London, United Kingdom

11 ^c Department of Neurology 1, Neuromed Campus, Kepler Universitaetsklinikum, Linz,

12 Austria

13 ^d Swiss Epilepsy Centre, Klinik Lengg, Zuerich, Switzerland

14

15 Correspondence address Adele James, Department of Psychology, Whitelands College,

16 University of Roehampton, London, SW15 4JD, United Kingdom, adele_roe@outlook.com

17

18 Conflicts of interest - none declared.

19 Funding – The present research was supported by a grant from the University of Roehampton
20 and the authors wish to thank the University for supporting their work. The funding source
21 had no involvement in the preparation and submission of this article.

22

23 Text body – 16,555 characters (including spaces)

24

25

26

27

28

29

30

31

32

33

34

35

36

37

38

39

40

41

42

43

44 The present research explored the role of the medial temporal lobes in object memory in unique
45 patient MR, who has a selective lesion to her left lateral entorhinal cortex. Two experiments
46 explored recognition memory for object identity and object location in MR and matched
47 Controls. The results showed that MR had intact performance in an object location task (MR =
48 .70, Controls = .69, $t(6) = .06, p > .05$), but was impaired in an object identity task (MR = .62,
49 Controls = .84, $t(6) = -4.12, p < .05$). No differences in correct recollection or familiarity
50 emerged. These results suggest a differential role of the entorhinal cortex in object recognition
51 memory. The current research is therefore the first patient study to demonstrate the role of the
52 lateral entorhinal cortex in object identity recognition and suggests that current medial temporal
53 lobe theoretical models concerning both object and recognition memory need a theoretical re-
54 think to account for the contributions of the entorhinal cortex in these processes.

55

56 Keywords: entorhinal cortex, recollection, familiarity, object recognition, memory

57

58

59

60

61

62

63

64

65

66

67

68

69 **Introduction**

70 A current issue within cognitive neuropsychological research concerns the role of the
71 medial temporal lobes in both memory and perception. Mnemonic-perceptual theories have
72 suggested that the medial temporal lobes are involved in both these processes, with the
73 perirhinal cortex responsible for object identity recognition and the hippocampus being
74 interested in spatial perception [1], [2]. However, the role of the entorhinal cortex, which is
75 situated between the hippocampus and perirhinal cortex, in both object recognition and spatial
76 perception remains little understood. This is partly due to the complete lack thus far of patients
77 with damage focal to the entorhinal cortex. Hence the present research aims to shed light onto
78 the role of the entorhinal cortex in these processes in a unique patient MR, who has a selective
79 lesion to her left entorhinal cortex.

80

81 Regarding object recognition, the two streams hypothesis proposes that different and
82 distinct ‘what’ and ‘where’ pathways exist in the brain [3], [4]. Part of these ‘what’ and ‘where’
83 streams ultimately reach the medial temporal lobes, where the information they contain is
84 bound into a single, unified representation by the hippocampus [5]. Although these ‘what’ and
85 ‘where’ streams are initially perceptual, it is believed that they become endowed with
86 mnemonic information as they enter the medial temporal lobes. Given the location of the
87 entorhinal cortex between the perirhinal cortex and the hippocampus, it has been speculated
88 that this area may also be involved in perceptual-mnemonic processes [6]. Relatedly,
89 subdivisions may also exist within the entorhinal cortex, where the lateral part has a
90 visuo-perceptual role and the medial part has a visuo-spatial role [7], [8]. Furthermore, it has
91 been found that lateralisation occurs for object encoding such that object identity encoding was
92 lateralised left, while spatial encoding was lateralised right within the medial temporal lobes
93 [9], [10].

94

95 As well as having a role in perception, the medial temporal lobes also underpin
96 recognition memory and the subjective experiences which accompany successful retrieval,
97 namely recollection and familiarity, or ‘remembering’ and ‘knowing’. Recollection involves
98 the retrieval of contextual information whereas familiarity is acontextual retrieval. Although
99 there is dispute whether these processes are independent or not, the evidence for these being a
100 dual process is strong at the brain level. Compelling fMRI evidence has demonstrated that the
101 hippocampus underpins recollection whereas the perirhinal cortex supports familiarity [5],
102 [11]. Patient studies have also been invaluable in supporting the dual-process model in finding
103 a clear double dissociation between remembering and knowing. [12 - 15].
104

105 At present, there has been no specific role suggested for the entorhinal cortex in any
106 theoretical recognition memory models, although recent research in healthy adults has
107 suggested that this area has a selective role in familiarity rather than recollection-based
108 judgements [13]. Recent research on patient MR, who has a selective lesion to her left
109 entorhinal cortex, demonstrated impaired familiarity for words but performed normally in the
110 recognition of non-words and faces [14]. Additionally, her recollection was unimpaired across
111 these entire stimuli. Relatedly, recent research [15] has explored these processes in relation to
112 material type in the medial temporal lobes, finding that the rhinal cortices responded
113 preferentially to object familiarity, but not to scenes or faces, whilst the hippocampus was not
114 material-specific but did respond to recollection for all category types. The aims of the present
115 research are therefore to investigate the role of the entorhinal cortex in object recognition and
116 associated subjective experiences, in MR and her Control group.
117

118 **Method**

119 The research gained ethical approval from the National Research Ethics Service and the
120 University of Roehampton Ethics Committee. All participants, including MR, gave written

121 informed consent. MR and eight Controls took part in the research. Control participants were
122 healthy females, all of whom had fluent English and were matched to MR on handedness, age,
123 years of education and a range of neuropsychological intelligence profiling, as detailed in
124 previous research [14]. All measures were tested using Crawford's modified *t*-test, which is
125 suitable for single case studies with a small control group [16] and all $p > .05$. Participants were
126 given monetary compensation for their travel and participation.

127

128 *Patient MR*

129 MR's clinical profile is more fully described elsewhere [14]. Briefly, she is a right-
130 handed female who was 51 years old at the time of testing. At the age of 36 she began to
131 experience seizures, and MRI investigations identified a small cavernoma on her left
132 parahippocampal gyrus. To localise the lesion in relation to the entorhinal cortex, coronal
133 images were compared with published references to the delineation of the entorhinal cortex
134 [17] and, to exclude any atrophy of the mesial temporal structures, automated volumetric
135 assessment was performed according to previously described methods [18]. This found that the
136 volumes of MRs medial temporal lobes are in-line with aged-matched Controls and, despite
137 her cavernoma, there is no atrophy present in this area. Imaging analysis was only performed
138 for MR and is shown in Figure 1.

139

140 *Experiment 1: object identity*

141 Participants gave written informed consent and were given a verbal description of the
142 experiment. Then, they were trained on the remember/know/guess paradigm, using instructions
143 closely modelled on previous work [19]. This experiment was designed to explore object
144 identity memory by manipulating the identity of objects from scenes. A practice block using
145 stimuli from the SUN database [20] was given to participants so they could familiarise
146 themselves with the demands of the experiment and to ensure they fully understood the method.

147 After finishing, participants were given the opportunity to ask any questions before proceeding
148 to the experiment proper.

149

150 Here, memory was tested for objects embedded in different 48 3D scenes adapted from
151 previous work [21]. Each scene was visually rich in colour, with shadows and lighting detail.
152 All scenes depicted a real-life environment, e.g. a kitchen. In a trial, participants were shown a
153 fixation cross for 1000ms before being shown a scene for 10 seconds, followed by a pattern
154 mask of patchwork colours for 200ms. Following this scene presentation, an object was then
155 presented centrally on an olive-green background. In half of the trials, this object was taken
156 from the initial scene (true trial), and in the other half the object was not present in the initial
157 scene (false trial). False trials used objects picked from the same practice trials of previous
158 research [21], which were not used in the present experiment. Participants were asked to decide
159 if the object was in the scene or not. If they agreed, they were then asked to make a
160 remember/know/guess decision. If the participant initially indicated that the object was not in
161 the scene, then the experiment skipped to the next trial. Presentation of trials was randomised
162 and responses were collected via keyboard. After the experiment was completed, participants
163 were fully debriefed, thanked for their time, paid and dismissed.

164

165 *Experiment 2: object location*

166 The procedure was almost identical to that of Experiment 1 and took place on average
167 almost 4 weeks after Experiment 1. However now, rather than the target object being presented
168 in the centre of the screen, a true object's location was manipulated. Again, half of the trials
169 were true (the object is presented in the same location as it was in the initial scene) and half
170 false (the object is moved to a false alarm position.). Only the location of the object was
171 manipulated in the present experiment to ensure that this task was only exploring object-
172 location memory. Other than this manipulation, the trials were virtually the same as described

173 in the object identity experiment. Participants were asked ‘Was this object located here in the
174 scene?’, where key presses indicated a yes/no, and asked if they remember / know / guess if
175 they answered ‘yes’. The debrief, payment, thanking and dismissal was the same as previously.

176

177 **Results**

178 One participant was excluded from both experiments for floor performance. Results
179 from the two experiments were analysed using the proportion of hits minus false alarms for
180 overall recognition, remember, and know responses. Guesses were too low to analyse but all
181 subjective measure results are included in Table 1. All results were analysed using Crawford’s
182 modified *t*-test [16]. In line with other similar patient research [22], remember responses acted
183 as an index of recollection, while a correction of independence was applied to know responses
184 [$F = K(1-R)$] in order to get an estimate of familiarity [23]. This correction of independence
185 assumes that recollection and familiarity are distinct, where recollection is proposed to be a
186 categorical threshold process, while familiarity is a continuous signal-detection process [24].
187 These data were also analysed without the correction of independence (hits minus false alarms).

188

189 *Experiment 1: object identity*

190 Three trials were excluded from the analysis as the objects chosen may have been
191 semantically linked to their respective scene, for example, a living room scene which contained
192 a lamp had a different lamp shown as the false alarm object, which could therefore have raised
193 the false alarm rate. All analyses are two-tailed unless otherwise stated.

194

195 The analysis on overall recognition performance (hits-false alarms) found that MR was
196 significantly impaired in comparison to Controls (MR = .62, Controls = .84, $t(6) = -4.12$, $p <$
197 .05, one-tailed). Additionally, analysing overall recognition memory using d' , based on signal
198 detection theory [25], showed that MR was also impaired when compared to Controls ($t(6) = -$

199 3.11, $p < .05$). MR's response criterion was measured using the criterion location measure (C)
200 [14], which revealed that MR had no shift in response criterion when compared to Controls
201 ($t(6) = 1.03$, $p > .05$). Further analyses revealed no significant differences in recollection (MR
202 = .58, Controls = .63, $t(6) = -.29$, $p > .05$), nor in familiarity (MR = .10, Controls = .30, $t(6) =$
203 $-.75$, $p > .05$, one-tailed).

204

205 Given MR's impairment in overall recognition performance, separate analyses on hits
206 and false alarms were carried out to determine where the nature of her impairment was located.
207 These analyses found that, in terms of hits, MR was impaired in overall recognition (MR = .67,
208 Controls = .86, $t(6) = -2.96$, $p < .05$) but performed within normal range for recollection (MR
209 = .63, Controls = .64, $t(6) = -.06$, $p > .05$) and familiarity (MR = .11, Controls = .30, $t(6) = -$
210 $.71$, $p > .05$, one-tailed). The analyses on overall false alarms showed no differences between
211 MR and the Controls (MR = .05, Controls = .02, $t(6) = .94$, $p > .05$), nor were any differences
212 found for recollection (MR = .05, Controls = .01, $t(6) = 1.87$, $p > .05$), and neither group made
213 any false know responses, hence familiarity rates are not calculated.

214

215 *Experiment 2: object location*

216 One trial was excluded from analysis as the location of the object coincided where a
217 similar object was in the original scene. Analysis was the same as described in Experiment 1.
218 The results revealed that there were no significant differences between MR and the Controls
219 for overall recognition memory, (MR = .70, Controls = .69, $t(6) = .06$, $p > .05$). Her d' score
220 was also normal in this task when compared to Controls ($t(6) = -.30$, $p > .05$), as was her C
221 score ($t(6) = -1.09$, $p > .05$). However, MR had significantly lower recollection compared to
222 Controls, (MR = .33, Controls = .52, $t(6) = -2.54$, $p < .05$). There were no significant difference
223 between MR and the Controls for the measure of familiarity (MR = .43, Controls = .25, $t(6) =$
224 $.77$, $p > .05$).

225

226 Given MR's impairment for overall remember responses, separate analyses on hits and
227 false alarms were carried out in order to explore this further. For hits, the analysis found that
228 MR was within normal range for recollection responses (MR = .42, Controls = .54, $t(6) = -$
229 1.40, $p > .05$) and familiarity (MR = .50, Controls = .33, $t(6) = 1.14$, $p > .05$). Analysis of false
230 alarms found that MR's overall scores were normal (MR = .13, Controls = .07, $t(6) = .80$, $p >$
231 .05), although the analysis revealed that MR gave significantly more false recollection
232 responses (MR = .09, Controls = .02), $t(6) = 3.27$, $p < .05$) but had normal levels of false
233 familiarity (MR = 0, Controls = .03, $t(6) = -.56$, $p > .05$).

234

235 **Discussion**

236 The aim of the present research was to explore the role of the left entorhinal cortex in
237 object recognition. The findings demonstrated that MR was impaired in recognising an object's
238 identity, but had normal object location memory. The remaining results found that MR
239 generally performed similarly to the Controls in terms of recollection and familiarity, although
240 she did report significantly more false remember responses in the Where experiment. Her
241 impairment therefore primarily only affects object identity recognition, while her spatial
242 memory is spared.

243

244 Perceptual-mnemonic theories would suggest that the perirhinal cortex underpins
245 object perception, whereas the hippocampus underpins spatial perception [1], [2]. As far as the
246 authors are aware, no such perceptual-mnemonic theory has yet formally suggested a role of
247 the entorhinal cortex in object processing, although there is existing neuroimaging evidence on
248 healthy participants suggesting that it does have a role to play in object processing [9]. More
249 recent work using a higher strength scanner has also broadly supported this notion [8], although
250 the precise nature of the human entorhinal cortex has yet to be fully understood. Lastly,

251 research has found that object identity and object location processing is lateralised to the left
252 and right hemispheres, respectively [9 - 10]. Taken together, these findings on healthy
253 participants strongly suggest that the entorhinal cortex has a role in object perception.
254 Moreover, the present patient research implicates the entorhinal cortex as being part of the
255 ‘what’ pathway, thus extending research on patients with perirhinal cortex damage who have
256 been found to be impaired in recognising an object’s identity. Furthermore, this result is
257 supported by MR’s imaging that demonstrates she has no atrophy within this area and that there
258 are no volumetric differences within her medial temporal lobe regions compared to age-
259 matched Controls. As her impairment can be confidently deduced to the cavernoma on the
260 lateral part of her left entorhinal cortex, this strongly suggests that this area is integral for object
261 identity recognition.

262

263 The present research explores the first single case study on a patient with a selective
264 lesion to the left entorhinal cortex in object recognition memory. Such populations offer
265 obvious localisation of function advantages in memory research, although caution must be
266 taken not to over-interpret the present findings. Further investigation is required to solidify the
267 role of the entorhinal cortex. For example, it would be of interest to see how a patient with a
268 lesion to their right entorhinal cortex might perform in these object memory tasks, as this would
269 shed light on whether the crux of MR’s object identity impairment is due to verbal labelling
270 processes that are left-dominant. A patient with such damage may therefore be unimpaired as
271 MR’s performance suggests that object recognition is resolved by the left, and not the right,
272 hemisphere.

273

274 In sum, the present research has demonstrated for the first time a unique relationship
275 between the entorhinal cortex and object identity but not object location memory. Furthermore,
276 given the generally normal correct recollection and familiarity levels demonstrated in patient

277 MR, our results suggest that the role the entorhinal cortex has to play in object identity
278 recognition is based mainly on quantitative aspects of recognition memory. Furthermore, this
279 appears to be restricted to the lateral part of the left entorhinal cortex. These findings suggest a
280 theoretical re-think of the role of the entorhinal cortex in mnemonic-perceptual accounts of the
281 medial temporal lobes.

282

283

284

285

286

287

288

289

290

291

292

293

294

295

296

297

298

299

300

301

302

303 Acknowledgements – We are grateful to MR for her very willing cooperation and interest in
304 our research.

305

306

307

308

309

310

311

312

313

314

315

316

317

318

319

320

321

322

323

324

325

326

327

328

329 **References**

- 330 [1] K. S. Graham, M. D. Barense, and A. C. H. Lee, “Going beyond LTM in the MTL: a
331 synthesis of neuropsychological and neuroimaging findings on the role of the medial
332 temporal lobe in memory and perception.,” *Neuropsychologia*, vol. 48, no. 4, pp. 831–
333 53, Mar. 2010.
- 334 [2] A. C. H. Lee, M. D. Barense, and K. S. Graham, “The contribution of the human
335 medial temporal lobe to perception: bridging the gap between animal and human
336 studies.,” *Q. J. Exp. Psychol. B.*, vol. 58, no. 3–4, pp. 300–25, 2005.
- 337 [3] M. a Goodale and a D. Milner, “Separate visual pathways for perception and action.,”
338 *Trends Neurosci.*, vol. 15, no. 1, pp. 20–5, Jan. 1992.
- 339 [4] M. Mishkin, L. G. Ungerleider, and K. A. Macko, “Object vision and spatial vision :
340 two cortical pathways,” pp. 414–417, 1983.
- 341 [5] R. a Diana, A. P. Yonelinas, and C. Ranganath, “Imaging recollection and familiarity
342 in the medial temporal lobe: a three-component model.,” *Trends Cogn. Sci.*, vol. 11,
343 no. 9, pp. 379–86, Sep. 2007.
- 344 [6] B. A. Kent, M. Hvoslef-Eide, L. M. Saksida, and T. J. Bussey, “The representational–
345 hierarchical view of pattern separation: Not just hippocampus, not just space, not just
346 memory?,” *Neurobiol. Learn. Mem.*, 2016.
- 347 [7] Z. M. Reagh and M. a Yassa, “Object and spatial mnemonic interference differentially
348 engage lateral and medial entorhinal cortex in humans.,” *Proc. Natl. Acad. Sci. U. S.*
349 *A.*, Sep. 2014.
- 350 [8] H. Schultz, T. Sommer, and J. Peters, “The Role of the Human Entorhinal Cortex in a
351 Representational Account of Memory,” vol. 9, no. November, pp. 1–8, 2015.
- 352 [9] P. S. F. Bellgowan, E. a Buffalo, J. Bodurka, and A. Martin, “Lateralized spatial and
353 object memory encoding in entorhinal and perirhinal cortices.,” *Learn. Mem.*, vol. 16,
354 no. 7, pp. 433–8, Jul. 2009.

- 355 [10] W. M. Kelley, F. M. Miezin, K. B. Mcdermott, R. L. Buckner, M. E. Raichle, N. J.
356 Cohen, J. M. Ollinger, E. Akbudak, T. E. Conturo, A. Z. Snyder, and S. E. Petersen,
357 “Hemispheric Specialization in Human Dorsal Frontal Cortex and Medial Temporal
358 Lobe for Verbal and Nonverbal Memory Encoding,” vol. 20, pp. 927–936, 1998.
- 359 [11] A. P. Yonelinas, “The Nature of Recollection and Familiarity: A Review of 30 Years
360 of Research,” *J. Mem. Lang.*, vol. 46, no. 3, pp. 441–517, Apr. 2002.
- 361 [12] K. R. Brandt, J. M. Gardiner, F. Vargha-Khadem, A. D. Baddeley, and M. Mishkin,
362 “Impairment of recollection but not familiarity in a case of developmental amnesia.”
363 *Neurocase*, vol. 15, no. 1, pp. 60–5, 2008.
- 364 [13] A. de Vanssay-Maigne, M. Noulhiane, A. D. Devauchelle, S. Rodrigo, S. Baudoin-
365 Chial, J. F. Meder, C. Oppenheim, C. Chiron, and F. Chassoux, “Modulation of
366 encoding and retrieval by recollection and familiarity: mapping the medial temporal
367 lobe networks.” *Neuroimage*, vol. 58, no. 4, pp. 1131–8, Oct. 2011.
- 368 [14] K. R. Brandt, M. W. Eysenck, M. K. Nielsen, and T. J. von Oertzen, “Selective lesion
369 to the entorhinal cortex leads to an impairment in familiarity but not recollection,”
370 *Brain Cogn.*, vol. 104, pp. 82–92, 2016.
- 371 [15] A. Kafkas, E. M. Migo, R. G. Morris, M. D. Kopelman, D. Montaldi, and A. R.
372 Mayes, “Material specificity drives medial temporal lobe familiarity but not
373 hippocampal recollection,” *Hippocampus*, vol. 209, pp. 1–20, 2016.
- 374 [16] J. R. Crawford and D. C. Howell, “Comparing an Individual ’ s Test Score Against
375 Norms Derived from Small Samples *,” vol. 12, no. 4, pp. 482–486, 1998.
- 376 [17] R. Insausti, K. Juottonen, H. Soininen, A. M. Insausti, K. Partanen, P. Vainio, M. P.
377 Laakso, and a Pitkänen, “MR volumetric analysis of the human entorhinal, perirhinal,
378 and temporopolar cortices.” *AJNR. Am. J. Neuroradiol.*, vol. 19, no. 4, pp. 659–71,
379 Apr. 1998.
- 380 [18] H. J. Huppertz, J. Kröll-Seger, S. Klöppel, R. E. Ganz, and J. Kassubek, “Intra- and

- 381 interscanner variability of automated voxel-based volumetry based on a 3D
382 probabilistic atlas of human cerebral structures,” *Neuroimage*, vol. 49, no. 3, pp. 2216–
383 2224, 2010.
- 384 [19] S. Rajaram, “Remembering and knowing: two means of access to the personal past.,”
385 *Mem. Cognit.*, vol. 21, no. 1, pp. 89–102, Jan. 1993.
- 386 [20] J. Xiao, J. Hays, K. A. Ehinger, and A. Torralba, “SUN database : Large-scale scene
387 recognition from abbey to zoo,” *IEEE Conf.*, 2010.
- 388 [21] A. Hollingworth, “The relationship between online visual representation of a scene and
389 long-term scene memory.,” *J. Exp. Psychol. Learn. Mem. Cogn.*, vol. 31, no. 3, pp.
390 396–411, May 2005.
- 391 [22] B. Bowles, C. Crupi, S. M. Mirsattari, S. E. Pigott, A. G. Parrent, J. C. Pruessner, A. P.
392 Yonelinas, and S. Köhler, “Impaired familiarity with preserved recollection after
393 anterior temporal-lobe resection that spares the hippocampus.,” *Proc. Natl. Acad. Sci.*
394 *U. S. A.*, vol. 104, no. 41, pp. 16382–7, Oct. 2007.
- 395 [23] A. P. Yonelinas and L. L. Jacoby, “Dissociating automatic and controlled processes in
396 a memory-search task: Beyond implicit memory,” *Psychol. Res.*, vol. 57, no. 3–4, pp.
397 156–165, 1995.
- 398 [24] A. P. Yonelinas and L. L. Jacoby, “The process-dissociation approach two decades
399 later: convergence, boundary conditions, and new directions.,” *Mem. Cognit.*, vol. 40,
400 no. 5, pp. 663–80, Jul. 2012.
- 401 [25] J. G. Snodgrass and J. Corwin, “Pragmatics of measuring recognition memory:
402 applications to dementia and amnesia.,” *J. Exp. Psychol. Gen.*, vol. 117, no. 1, pp. 34–
403 50, 1988.

404
405
406

407 **Figures and tables** (to be inserted by journal)

408 **Table 1.**

409 Proportion of hits and false alarms for MR and Controls as a function of experiment type.

410

	Hits			False alarms		
	Remember	Know	Guess	Remember	Know	Guess
<i>Exp. 1:</i>						
MR	.63	.04	0	.05	0	0
Controls	.64 (.16)	.13 (.15)	.10 (.06)	.01 (.02)	0 (0)	.01 (.02)
<i>Exp. 2:</i>						
MR	.42	.29	.13	.09	0	.04
Controls	.54 (.08)	.15 (.07)	.08 (.08)	.02 (.02)	.03 (.05)	.02 (.03)

411

412 *Note.* Standard deviations in parentheses

413

414

415

416

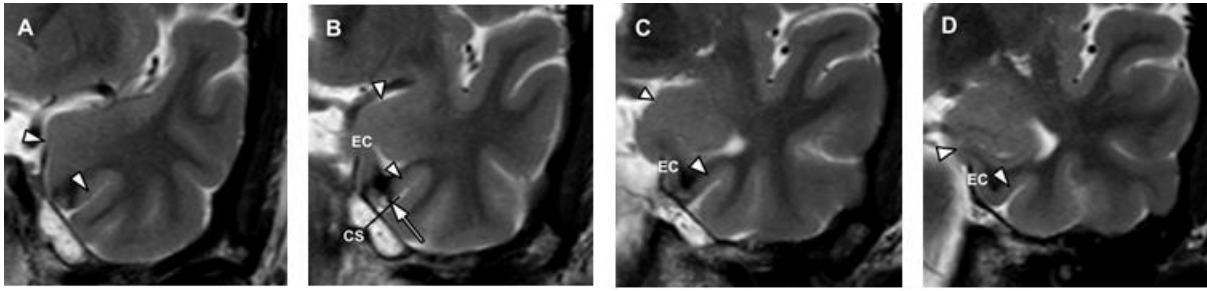
417

418

419

420

421



422

423

424

425

426

427

428

429

430

431

Figure 1. T2-weighted coronal imaging of MRs cavernoma (white arrow, EC = entorhinal cortex; CS = collateral sulcus). Orientation of the coronal images is perpendicular to the longitudinal axis of the hippocampus and slice thickness is 2 mm. Following previous protocol [17], this series of images shows the landmarks used to identify the hippocampal and rhinal cortical areas. It would appear that MR's cavernoma and its surrounding hemosiderin halo (surrounding susceptibility artefact = black) covers the lateral part of the left entorhinal cortex, as in [7].