



King's Research Portal

DOI:

[10.1016/j.fri.2020.200420](https://doi.org/10.1016/j.fri.2020.200420)

Document Version

Peer reviewed version

[Link to publication record in King's Research Portal](#)

Citation for published version (APA):

Varela Morillas, A., Nurgaliyeva, Z., Gooch, J., & Frascione, N. (2020). A review on the evolution and characteristics of post-mortem imaging techniques. *Forensic Imaging*, 23, [200420].
<https://doi.org/10.1016/j.fri.2020.200420>

Citing this paper

Please note that where the full-text provided on King's Research Portal is the Author Accepted Manuscript or Post-Print version this may differ from the final Published version. If citing, it is advised that you check and use the publisher's definitive version for pagination, volume/issue, and date of publication details. And where the final published version is provided on the Research Portal, if citing you are again advised to check the publisher's website for any subsequent corrections.

General rights

Copyright and moral rights for the publications made accessible in the Research Portal are retained by the authors and/or other copyright owners and it is a condition of accessing publications that users recognize and abide by the legal requirements associated with these rights.

- Users may download and print one copy of any publication from the Research Portal for the purpose of private study or research.
- You may not further distribute the material or use it for any profit-making activity or commercial gain
- You may freely distribute the URL identifying the publication in the Research Portal

Take down policy

If you believe that this document breaches copyright please contact librarypure@kcl.ac.uk providing details, and we will remove access to the work immediately and investigate your claim.

A review on the evolution and characteristics of post-mortem imaging techniques

Abstract: Up until the beginning of the 21st century, the technique of choice for the forensic medical examination of a deceased individual was the traditional medical autopsy. This, however, has begun to change with the introduction of post-mortem imaging. Post-mortem imaging, or 'virtual autopsy', is a novel area of radiology that utilises non-invasive imaging techniques for the examination of a body. Many of the techniques used to conduct a virtual autopsy are more commonly employed within clinical diagnostic, such as computed tomography or magnetic resonance imaging. In recent years, post-mortem imaging has gathered significant momentum as a robust and objective methodology capable of compiling relevant intelligence without disturbing a body. This review identifies and describes the techniques currently available for post-mortem imaging and provides an insight on their advantages and disadvantages compared to traditional autopsy methods. The aim of this paper is to highlight the most relevant milestones accomplished in this field and the potential application of this technique within current forensic frameworks.

Keywords: post-mortem imaging, virtual autopsy, forensic medical examination, radiology, computed tomography, magnetic resonance imaging.

1. Introduction

Forensic medicine often involves the application of every branch of medicine to provide clinical evidence that can be delivered in court. This is obtained through the assessment of individuals, who might have been injured or killed [1]. One of the most challenging tasks for any forensic pathologist is determining the cause of death of an individual and any factors that can provide essential information for the resolution of an investigation. This is usually achieved using a process known as a 'post-mortem' or 'autopsy'. The post-mortem remains a relevant technique that provides important insight on the different pathological processes that the human body can undergo.

However, traditional autopsy is a time-consuming technique with significant financial costs. Additionally, there is also the issue that certain religions and/or cultures do not allow any form of bodily intrusion, limiting the type of examinations that can be carried out. As a result, there have been calls for the modernisation of forensic medical examination. A resolution could be found in the use of post-mortem imaging, a series of techniques, commonly grouped under the term of 'virtual autopsy', that are beginning to find routine employment in legal investigations [2].

Virtual autopsy is well recognized for its capability to report relevant evidence from a body using minimally invasive, non-destructive techniques [2]. This review will highlight the progress that has been made in this field so far, with a focus on the techniques that are most used in forensic examination. The information gathered here will shed some light on the advantages and disadvantages of these methods and their potential implementation as routine techniques in legal investigation. It will also provide some insight on their different potential applications in forensic medical examination, something that has yet to be discussed in detail.

2. History of the Virtual Autopsy

One of the most used techniques in the field of radiology is X-ray documentation. X-rays have been used for forensic medical examination almost since their discovery. In fact, the first X-ray image of a corpse as part of a criminal investigation was taken in 1898 [3]. In routine practice the examiner takes a series of X-ray images of the area of interest, which can act as evidence in court. This, however, is a tedious process since the possibility of skeletal fractures is often considered only after the external examination. Any subsequent examinations will require transporting the body to an X-ray facility, increasing the time needed and potentially losing any evidence on the body. Other limitations of this technique are the inability to obtain other information besides macroscopic features of the bones or the potential presence of foreign bodies (meaning that the technique cannot replace a full-body autopsy when it comes to soft tissue examination), as well as the costs associated with the safety equipment necessary to protect the operators from radiation [4].

As a result, newer techniques, such as Computed Tomography (CT) and Magnetic Resonance Imaging (MRI), rapidly replaced X-ray imaging. The first CT device was released in 1972 [5], quickly followed by MRI in 1973 [6] and although the initial prototypes offered very limited image quality, both methods were immediately embraced in the field of radiology. These techniques saw a rapid development in the 70s and 80s, becoming fast examination methodologies that provide high-resolution images of the internal structures of the human body in a significantly shorter time frame. It was this fast development that attracted the interest of experts in the use of both CT and MRI in post-mortem examination in the late 80s and early 90s. It was around this time that the first use of post-mortem imaging in a legal inquiry was reported in the US. In 1997, photographs taken of a motorist a few days after an incident were compared against data from CT and MRI to establish the relation between external patterned injuries and the deeper tissue damage to determine whether blows from a police baton landed in the victim's craniofacial area or not [7].

The rapid development of these techniques has caused some authors to question whether traditional autopsy methods can be replaced entirely with imaging-only approaches [8]. The first publication suggesting this was released in 2000. In this study, the authors recreated an injury on from a real forensic case and used imaging techniques such as CT and MRI to study the sub-surface morphological damage caused by the weapon. Their results demonstrated the ability of imaging techniques to provide accurate information without changing or damaging evidence [9]. In the United Kingdom, post-mortem imaging has also been applied to forensic casework, particularly for the examination of projectile injuries [10] and in mass disaster victim identification [11,12]. Meanwhile, in 2007, forensic scientists from the Victorian Institute of Forensic Science (Australia) described the use of Multi-slice Computed Tomography (MSCT) in the investigation of mass disaster cases involving plane crashes to provide fast and effective identification and reconciliation of body parts found at the scene. The authors of this study emphasized that the installation of MSCT in mortuaries would open up great prospects for forensic and legal investigation [13].

3. Current Techniques for Post-mortem Imaging

3.1 Computed Tomography (CT)

CT is a non-destructive method used for studying the internal structure of the body. The method is based on the measurement and complex processing of the attenuation of X-ray radiation by

tissues of different density [14]. Currently, CT is the main method for studying internal organs. The scientific and technological development of CT scanners is directly related to the progress and development of new detectors. The first generation of CT scanners appeared in 1972 [5]. These devices utilised a 'step-by-step' methodology, with one X-ray tube (the emission source) aimed at a small set of 30 detectors (one at a time) as the tube translated across the body and then rotated around to scan the next section. This scanning was done by one revolution per layer, which meant that each scan would take approximately 18 seconds to perform. For the second generation, a 'fan' type design was used in which detectors (usually 300-500) were mounted on a rotation ring opposite to the X-ray tube. Since the detectors in this array only covered a small section of the body, this layout required for the detectors to be fully stabilised for good resolution. However, this design helped reduce scan time to 3 seconds. The third generation of CT employed an array of 700-1000 detectors set on a fixed ring. With these devices, only the X-ray tube would rotate around the body, also resulting in a scan of 3 seconds but without the need for detector stabilisation, thereby increasing image resolution and reducing the incidence of artefacts due to unexpected motions [14]. Recently a novel modality of CT, known as spiral-computed tomography, has been developed. This new generation of instruments can, in one step, have the X-ray tube and the detectors synchronously rotate clockwise, reducing the screening time which, as a consequence, decreases the time that the patient must spend in the scanner as well as reduce the incidence of artefacts generated by small movements (such as breathing) [15]. In general, CT shows greater speed and resolution compared to conventional tomography. Furthermore, CT also shows greater sensitivity, as the beam is passed exclusively through the plane or side of the body, whereas traditional tomography would frequently produce a series of artefacts due to unwanted information from material at either side of the slide [14].

Currently, PMCT has proven to be a valuable technique for the detection of radio-opaque objects and the identification of traumatic processes such as blunt force or haemorrhage, and especially in osseous lesions; when compared to traditional autopsy [10,16-20]. However, this technique shows a limited visualization of soft-tissue, making it unsuitable for the study of non-traumatic deaths, such as ischaemic heart disease or pulmonary embolism [20].

3.2 Multi-slice Computed Tomography (MSCT)

MSCT, also known as Multidetector Computed Tomography (MDCT), was first introduced by Elscint Co. in 1992 [21]. The difference between MSCT and spiral tomography from previous generations is that not one, but two or more rows of detectors are located around the circumference of the gantry. In 1992, the first two-slice (double-helix) MSCTs consisted of two rows of detectors. By 1998 a four-slice (four-spiral) MSCT was released with four rows of detectors. These additional units of data acquisition doubled and quadrupled the speed of data collection over single-section data scanners, respectively [22]. These modifications also allowed for the number of revolutions of the X-ray tube to be increased from one to two per second. These combined features managed to increase the scanning speed to eight times over single-section CT [22]. Additionally, the presence of multiple detector rows means that slice thickness is not determined by the X-ray tube but by the configuration of the detectors, known as detector collimation [22,23]. This allows the scanning of thinner sections, leading to increased spatial resolution. Moreover, increased speed contributes to an improved temporal resolution due to a lower incidence of motion artefacts and also allows for a faster administration of intravenous contrast solutions, thereby improving the performance of contrast imaging [22]. More recently, the number of detector rows has increased from 4 to 64 and even up to 320-slice systems. This has significantly increased the speed and resolution while also reducing radiation dose to patients

and operators. This increase in quality and speed has turned MSCT into a valuable technique not only for structural analysis but also for 'real time' physiological function studies [24].

3.3 Post-mortem Computed Tomography Angiography (PMCTA)

Unless a combination of factors coexists, such as severe and circumferential vascular calcification and/or extensive accumulation of intravascular gas [25], the examination of vascular structures with unenhanced PMCT is challenging. Hence why in 2008, Grabherr *et al.* studied the use of a modified heart-lung bypass instrument to perfuse an iodized oil-based solution as a contrast agent into the cardiovascular system of four different bodies by cannulation of the right femoral artery [26]. In no more than 3 minutes after the perfusion, visualisation of cardiovascular structures was attempted using MSCT. A panel of four board-certified experts (one anatomist, one radiologist and two pathologists) then evaluated the resulting angiograms. Final reports showed that the new technique effectively visualised even small supplying and draining vessels and that the examining experts were able to outline vascular changes and damages caused by self-IV drug administration and other pathological factors.

PMCTA has slowly become the standard technique for the examination of suspected cardiovascular pathology and injuries. It is especially effective for pinpointing the source of haemorrhage in areas that are delicate and/or not easily accessible with traditional autopsy, such as cerebrovascular injuries [27] or other scenarios of suspected vascular trauma like surgical error [28,29], arterial disease [28,30] or traumatic death [31,32]. Further research is also currently being undertaken to adapt this technique to more complex structures, such as in the investigation of coronary pathologies [33-35].

3.4 Magnetic Resonance Imaging (MRI)

MRI employs a magnetic field and radio frequency (RF) signals to generate anatomical images to study the structure of the human body, detect pathological conditions and monitor various physiological processes. Originally based on the scientific background of Nuclear Magnetic Resonance (NMR) spectroscopy, the possibility of using NMR to generate spatial maps of spin distribution of an object was first proposed in 1973 by Paul Lauterbur [6]. By 1980, full-body NMR scans were made available, with clinicians studying their applicability to medical diagnosis by 1981 [36]. It was during these studies that experts observed that MRI had a contrast far superior than X-ray CT. Moreover, this contrast could also be adjusted by changing the settings of the radiofrequency of the pulses. With these features, along with its readily available multiplanar and three-dimensional technology, MRI quickly became a highly desirable technique [36].

Current MRI instruments display RF signals emitted by the tissue during the imaging process. These signals are the result of the magnetization produced when the tissue is placed in a strong magnetic field. The visibility of physical features in an MRI image is often highly dependent upon how the magnetic field is shifted during the acquisition process. The imaging process itself consists of an acquisition cycle that is repeated several times to cause magnetization [37]. MRI generates images that are significantly different from those generated by other imaging techniques. For example, MRI can simultaneously and exclusively image several features from the same tissue. This is advantageous in scenarios where a pathologic process has a targeted effect exclusively on some features of the same tissue, making it more likely to be detected [37].

In addition to this, MRI is also capable of monitoring chemical shifts in cells that could be used to track metabolic processes in real time [36].

3.5 3D Surface Scanning

Beyond the examination of internal injuries, some radiological techniques have been used for the documentation of external injuries [38]. This task used to be performed through traditional photography, allowing the comparison of a wound with different potential injury-causing objects and, with deeper wounds, by inserting a swab into the wound [39]. However, the potential destruction of evidence through this process and its two-dimensional nature limit its usefulness [38,40]. It was because of this that experts started to look into the use of other non-contact digital imaging techniques [38,39].

Some of the first studies describe the use of photogrammetry for the examination of external injuries [39]. This process involves the computerisation of colour- and light-balanced information from photographs to extract geometrical information. Photogrammetry software may be used to produce accurate data on the size, depth and volume of an injury from a two-dimensional image. Some early studies proposed the use of photogrammetry for the matching of vehicle tire marks left on the heads of victims during pedestrian-vehicle collisions. In these studies, accurate digital models were produced of injuries and successfully matched them, proving the usefulness of this technique not only in the study of flat weapons but also in more complex objects, such as tires [41]. However, this technique was also found to be limited by its low image resolution, preventing its use in the assessment of smaller wounds. To overcome this, studies on the use of a newer version of photogrammetry, known as forensic three-dimensional/computer aided design (CAD)-supported photogrammetry (FPHG), were undertaken [38,42,43]. With FPHG, morphological data of both injury and potential injury-causing objects are gathered through a series of photographs. These are then analysed with digital software to measure relevant morphological points to create accurate digital 3D models of each object. Then, using the 3D/CAD programme, the model of the injury is compared against the model of the potential injury-causing object to provide a match or exclusion [38,42,43]. More recently, this technique has been automated, significantly reducing the presence of human error during model building [44]. Moreover, experts are studying the combination of this technique with other radiological instruments such as MSCT and MRI, and with animations from real data, for the reconstruction of traffic accidents [40], as well as its use in the examination of injuries in living individuals [45].

3.6 Multimodal Imaging (MMI)

In recent years, many experts have proposed that a combined approach to 3D post-mortem examination may be more beneficial than the use of a single standalone technique. This approach, known as Multimodal Imaging (MMI), was first reported by Aalders *et al.* in 2017 [46]. It was discussed that the rapid development of new technologies for data analysis and processing has made it possible to merge information gathered from different techniques over multiple time frames and morphological points for a new way of visualizing information. Since then, it has been proposed in further studies that the combined use of all these techniques could resolve current issues related to analytical accuracy of post-mortem imaging techniques when used alone [47].

This new approach, whilst still in its infancy, is consistently being improved. Studies have already been carried in the combination of macroscopic and microscopic imaging techniques for obtaining information with enhanced spatial resolution [48], as well to provide new ways of

synthesising and displaying the information using novel 3D and 4D displays (and even through animation or virtual reality) [49-51].

4. Applications of virtual autopsy

The techniques previously discussed have demonstrated their applicability in the examination of internal morphological features and have been exploited for the following forensic purposes:

4.1 Accidental Deaths by Blunt Force Trauma – In scenarios of blunt force trauma, techniques like PMCT and PMCTA have proven to be better methods than traditional autopsy for the detection of skeletal injuries, detecting significant fractures that were missed by physical investigation. Moreover, PMCT was able to effectively depict and outline small fractures in areas that are not easily accessed with traditional autopsy, such as the facial bones or the vertebral column. This shows that these techniques can prove valuable in the identification and classification of injuries associated with accidental death through blunt force trauma [17,52-54].

4.2 Aging of the Deceased – The use of three-dimensional geometric morphometric analysis of sections of large bones, such as the femur, the pelvis or the ribs, using PMCT, allows the identification of age-related features. Said features could be used to establish the age of the deceased at the time of their death [55-58]. To do this, a series of relevant geometrical landmarks are examined, from morphological features, such as the bicondylar breadth (BCB) in the case of the femur [55] or the inter-pubic distance in the case of the pelvis [57]; to age-related physiological processes like the ossification around sternum and ribs ends [58]. These different features may be imaged and processed using data analysis software. Studies have concluded that macroscopic ossification and degeneration patterns can be accurately correlated with age, thus making it possible to differentiate individuals younger or older than 40 years old in the case of distal femur and “chest plate” examination [55,56,58] and establish a trend in morphological changes in the ages between 15 to 70 years old in the case of the pelvis [57].

4.3 Burned Bodies – PMCT is valuable for the examination and categorisation of charred human remains [59]. In their study, Blau et al investigated the use of PMCT in the examination of 41 bags containing charred human remains potentially belonging to two or more separate individuals. After two days of examination, the authors managed to reconcile 34 of those bags to two individuals. It was concluded that the ability to digitally erase the soft tissue layers to view the skeletal remains allowed the examiners to more rapidly inspect and categorise remains for further confirmation with other techniques [13]. The use of MSCT and MRI in the examination of charred bodies may also help in establishing the height, sex, age and other anthropometric information of the deceased through the examination of morphological features of the skeletal remains once they have been attributed to a single individual [60].

4.4 Dental Identification – The use of preventive odontology has significantly decreased the need for dental restoration, reducing the presence of dental identifiers frequently exploited in traditional autopsy. In their study, Franco *et al.* observed that, from a sample of 103 bodies that underwent a full-body CT scan; 91 had teeth and from those 91 individuals, 16 of them had never received any kind of dental treatment (thereby limiting the potential for identification). However, the authors of this study also noted that the use of 3D image reconstruction allowed for the identification of additional morphological identifiers not previously discussed in the Interpol dental codes. Furthermore, the 3D image reconstructions allowed to specify the location and volumetric features of these identifiers. It was concluded that the combined use of PMCT and 3D

reconstruction could potentially improve identification outcomes from the dental examination of highly damaged remains [61].

4.5 Drowning – A major challenge during the examination of remains found in water is determining whether death was caused via drowning. Several studies recently have been carried out on the use of imaging for the correlation of different internal pathological changes and drowning. In their study, Leth and Madsen observed that the combined information from the comparison of the radio densities of the blood in the heart chambers and the PMCT-measured total lung volume may allow experts to establish cases of drowning in water (**Figure 1**). This, however, did not make it possible to determine whether the death occurred in sea or fresh water [62]. In a study by Kawasumi *et al.*, it was observed that the accumulation of fluid in the maxillary or sphenoidal sinuses, which can be easily visualised using PMCT, is more common in drowning victims than those that died via other means (but whose remains were still found in water). The following year the same authors observed in a new study that the volume and density of fluid accumulation in the maxillary or sphenoidal sinuses differed significantly between drowning and non-drowning victims, providing further information for identifying this cause of death [63]. Two years later, a study by Bolliger *et al.* showed that the presence of waterborne foreign bodies in the internal cavities of human remains is indicative of drowning and that the presence of these foreign bodies, such as shell fragments, can be visualised using PMCT [64].

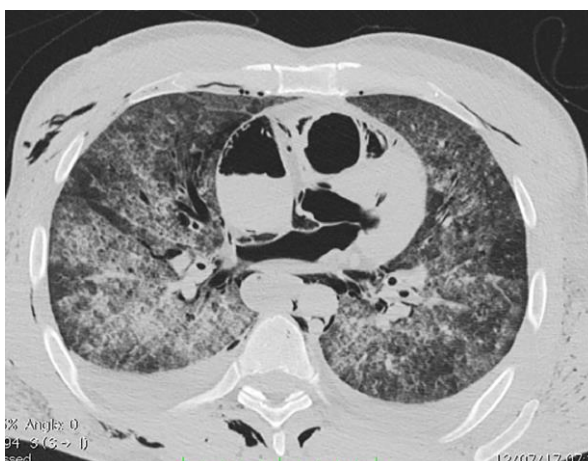


Figure 1: Axial PMCT at thorax level used in a case of suspected drowning. Figure reprinted with permission from Filograna L, Pugliese L, Muto M, Tatulli D, Guglielmi G, Thali MJ, Floris R (2019) A Practical Guide to Virtual Autopsy: Why, When and How. *Semin Ultrasound CT MR* 40 (1):56-66. doi:10.1053/j.sult.2018.10.011 [2]

4.6 Gunshot wounds – Traditional radiography is frequently used for the examination of gunshot wounds and for the location of bullets in the body. However, the sensitivity to metallic fragments and the possibility of 3D imaging from techniques such as MSCT [65] could prove helpful in identifying the site of lethal injury and the prediction of gunshot wound tracks (as observed in **Figure 2**). Levy *et al.* examined 13 gunshot wounds with a 16-section MSCT followed by traditional autopsy. The study showed that MSCT aided in the correct identification of all lethal wounds and had a 100% precision in the location of metallic fragments [65]. In a similar investigation, Valdes *et al.* studied the use of PMCT followed by traditional autopsy and showed that post-mortem imaging can be used for the accurate measurement and profiling of bullets trapped in the body of living victims that cannot be extracted through surgery [16].

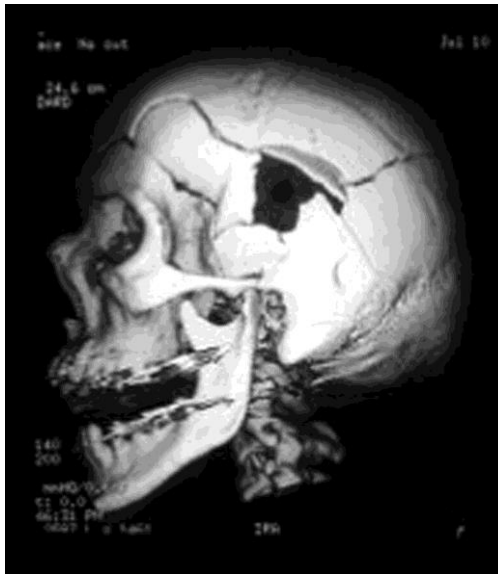

Figure 2: 3D-MSCT of a gunshot injury where the exit wound is visible by looking through the entrance wound. Figure reprinted with permission from Thali MJ, Jackowski C, Oesterhelweg L, Ross SG, Dirnhofer R (2007) VIRTopsy - the Swiss virtual autopsy approach. *Leg Med (Tokyo)* 9 (2):100-104. doi:10.1016/j.legalmed.2006.11.011 [66]

4.7 Infection – The use of post-mortem imaging has proven to be a valuable tool for the examination of suspected infections. Previous studies and case reports suggest that the use of techniques such as PMCT [67-72] and MSCT and MRI [73] can provide nearly as much or more information than traditional autopsy, with some examples where post-mortem imaging managed to identify new diagnostic signs of septicaemia not previously exploited [68,72]. Furthermore some of these studies showcase the value of these non-invasive techniques for their ability to (a) protect the examiner from high risk infectious diseases that might not have been previously identified [70,71]; and (b) guide the pathologist in a more targeted examination of areas that may have been overlooked in a standard autopsy protocol [69].

4.8 Suicide - PMCT can assist in the investigation of suspected suicide by giving more accurate information on the cause of death through three-dimensional image reconstruction. This technique has been utilised in cases of potential self-hanging for the visualisation of ligature marks around the neck, especially in scenarios where these marks are not easily detected through visual examination, such as in cases of thin ligatures or when it is difficult to differentiate the mark from the skinfolds due to the weight of the individual [18]. Furthermore, muscular lesions, which are not visible even with unenhanced PMCT, can be identified through associated haematomas and vascular lesions, visible with PMCTA [74]. Additionally, PMCT and MRI are also useful in finding and identifying bullets and the projectile trajectory in cases of suicide with firearms [75].

4.9 Traffic Accidents – PMCT can also be a vital tool in the investigation of road traffic accidents. In a study by Moskala *et al.* it was found, through the evaluation of 48 separate cases of road traffic accident, that the accuracy of PMCT is, at least, in concordance with traditional autopsy [19]. Furthermore, PCMT was able to find more information than manual autopsy in certain cases, such as skull, clavicle or scapula fractures. In a related study by Leth *et al.*, 994 different injuries from 67 different road traffic accidents were studied and a comparison of the performance of autopsy and PMCT was carried out. Out of these 994 injuries, only 5% were successfully identified with traditional autopsy, whereas PMCT was able to correctly identify 12%. However, it was also stated that a combined approach of both techniques managed to

successfully identify 83% of these injuries, proving that, even if post-mortem imaging cannot be used exclusively, it is still a powerful supporting technique that should be used in combination with traditional autopsy [76].

5. Advantages and Limitations of Virtual Autopsy

The techniques discussed within this review: PMCT, PMCTA, MSCT, MRI, 3D scanning and Multimodal Imaging, have shown great promise in post-mortem examination. However, prior to their implementation, their advantages and disadvantages need to be weighted. These have been outlined in **Table 1**.

Table 1: Overview of the advantages and disadvantages of X-ray, Post-Mortem Computed Tomography (PMCT), Multi-Slice Computed Tomography (MSCT), Post-mortem Computed Tomography Angiography (PMCTA), Magnetic Resonance Imaging (MRI), 3D Scanning and Multimodal Imaging. Adapted from “Post-mortem imaging in forensic investigations: current utility, limitations, and ongoing developments” by Grabherr *et al*, 2016 [77].

Method	Advantages	Disadvantages
X-ray	<ul style="list-style-type: none"> •Fast analysis •Easy to use •Simplified data storage •Low cost •Visualisation of skeletal features •Detection of foreign bodies 	<ul style="list-style-type: none"> •Need for radiation protection •No 3D reconstruction •Limited application in soft tissues •Superimposed images •Output quality dependant on acquisition
PMCT	<ul style="list-style-type: none"> •Fast analysis •3D reconstruction capability •Low cost •Visualisation of both skeleton and gaseous deposits 	<ul style="list-style-type: none"> •Need for radiation protection •Limited data storage •Limited application in soft tissue •Specialised training needed for handling
MSCT	<ul style="list-style-type: none"> •Larger imaging range •Fast analysis •Visualisation of microstructures •Real-time monitoring of physiological processes 	<ul style="list-style-type: none"> •Long processing times •Need large digital storage capacity •Need training for accurate interpretation •Higher radiation dose than single slice CT
PMCTA	<ul style="list-style-type: none"> •Visualisation of vascular structures •Low extravasation rate of contrast •Flushing of blood clots •Allows visualisation of specific structures •3D reconstruction capability 	<ul style="list-style-type: none"> •High equipment costs •Time consuming •Need for radiation protection •Need training for body preparation and accurate interpretation
MRI	<ul style="list-style-type: none"> •Application in soft tissues, organs and vascular walls •No radiation exposure •Can provide chemical information 	<ul style="list-style-type: none"> •High costs and time consuming •Need specifically designed infrastructures •Limited data storage •Need training for accurate interpretation
3D Surface Scanning	<ul style="list-style-type: none"> •Application in surface examination •3D reconstruction capability •Comparison of weapons and injuries •No radiation exposure •Low cost •Compatible with animation technology •No infrastructures requirements 	<ul style="list-style-type: none"> •Limited to surface examination •Need specialised training for accurate model construction •Time consuming •Need specialised software
Multimodal imaging	<ul style="list-style-type: none"> •Higher accuracy •Higher image resolution •Combined information of surface and Internal injuries 	<ul style="list-style-type: none"> •Not enough scientific background •High costs and time consuming •Need large digital storage capacity •Need training for accurate interpretation

An obvious advantage is the reduction of the necessary time for examination, in comparison to traditional autopsy. For example, a full body CT scan will require 5 to 15 minutes, a full body MRI will take no more than 30 minutes [3] and a tenth of the length for a CT scan in the case of MSCT [78]. A full examination from the start of the scan to the study of the images obtained and formation of the report can be done in 2.5 hours [60]. On average, the production of a full report can take from 1.5 to 3-4 hours with additional analysis; unlike traditional autopsy, where the procedure alone takes minimum 3 hours. Modern post-mortem imaging techniques also allow for more accurate and measurable information to be obtained from injuries and other pathological processes that cannot be easily discerned through visual examination (e.g. present in microstructures) or that are not easily accessible during traditional autopsy (e.g. brain haemorrhages or facial bone microfractures).

In addition, the use of post-mortem imaging represents a suitable alternative in countries where traditional autopsy is restricted due to cultural or religious reasons. In countries where performing an autopsy is still a challenge, such as Saudi Arabia or Qatar, studies on the use of MSCT and MRI have already been carried out for this purpose. These studies have proven the applicability of post-mortem imaging and how their low degree of invasiveness would make them acceptable under current cultural limitations (**Figure 3**) [79].

Another advantage is that techniques like PMCT and MRI show great sensitivity (low number of false negatives [80]), this nearing a concordance of 100% with traditional autopsy in some scenarios, such as in the diagnosis of pneumothorax [81] or in the detection of metallic fragments within the body [65]. On this very topic, past and recent systematic reviews have shown that imaging techniques, especially PMCT and MRI, are equally or more powerful diagnostic techniques than traditional autopsy in certain scenarios. This is particularly true in cases of traumatic injuries and intracorporeal liquid or gas accumulations, as observed by Jalalzadeh et al [54]; as well as in the visualisation of relevant diagnostic signs for aortic dissection, shown in the review by Ampanozi et al [82]. It is generally agreed in these and other systematic reviews that, in scenarios where the applicability of traditional autopsy is limited, post-mortem imaging can assist in achieving a more accurate diagnosis in these particular cases [54,82-85].

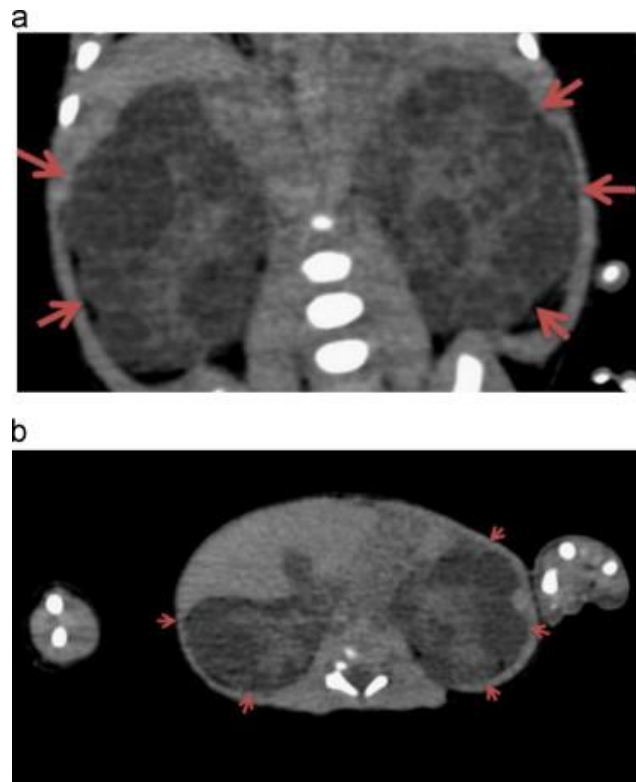


Figure 3: a) Coronal and (b) axial mid-abdomen cross-sectional CT image used for the diagnosis of Autosomal Recessive Polycystic kidney disease (ARPKD) in Saudi Arabia. Figure reprinted with permission from Algerian K, Alhawas A, Alqahtani S, Golding B, Alkahtani T (2015) First virtual autopsy in Saudi Arabia: A case report with literature review. *J Forensic Radiol Im* 3 (1):76-79. doi:10.1016/j.jofri.2014.11.002 [79]

Furthermore, since digital files are generated, all information gathered can be easily stored in digital records. This opens the path to fast and easy information sharing between experts around the world for discussion or even audit [86]. This also means that the images can be easily displayed in court, preventing the jury from been exposed to gruesome medical images whilst also providing information that traditional 2D photography cannot convey (such as wound trajectories). Linked to this feature, a final advantage of virtual autopsy is its potential application in education, as the digital images created with these techniques could be used to teach general anatomy in institutions where biological material is not available [3].

However, there are also disadvantages associated with these techniques that must be considered. The main limitation for touch-free autopsy is the high cost associated with these techniques, including both equipment and staff training. According to the 2012 report from the NHS Implementation Sub-Group of the Department of Health Post-mortem Forensic and Disaster Imaging Group, the average cost for a traditional autopsy in England was £96.80 for a single examination, whereas the estimated cost for a single examination through cross-sectional imaging, which does not include costs for any additional laboratory tests or the court attendance fees, could range from £279.00 up to £2460.00 in cases of Home Office investigation [87]. There may also be additional costs also associated with the setup and maintenance of the imaging equipment itself, such as the need for specialised architectural infrastructure that can house large machinery.

Finally, experts should also be cautious when considering the information gathered within the current literature, since the scientific publications available on virtual autopsy are mainly based on a small volume of cases studied, the minimum number of cases is from 1 to 3 [88], in which a comparative analysis of MSCT, MRI and traditional autopsy was performed; and the maximum

number in some cases being 182 [20]. Furthermore, previous systematic reviews have shown that there is a significant variability in the design of past studies, with differences not only in the sample size but also on the experimental design, the imaging process, the definition of the standard method(s), the terminology and the blinding [54,83-85]. It is agreed among experts that current studies are insufficient and further development and testing, as well as proper standardisation of the experimental protocols, is still required, as pointed by Eriksson et al and other authors [54,83-86,89]. Once proper guidelines for forensic and medical examination through imaging techniques have been set, it is expected by the experts that the quality of both forensic and clinical evidence will be enhanced [85].

6. Conclusions

A review of the literature has shown that novel techniques for post-mortem imaging are currently being evaluated for forensic applications. These techniques have proven to be at least as accurate as traditional autopsy and can provide further information that would normally remain undiscovered during traditional examination, whilst also allowing for the rapid, interactive and touch-free study and comparison of injuries.

However, despite the benefits of these techniques, it is likely that conventional autopsies will still be required in complex cases where the clinical and radiological diagnosis of cause of death is inconclusive. Nevertheless, post-mortem imaging can still be an indispensable tool for autopsy, making the invisible visible and improving the quality of examination. Moreover, these new methods open the path to broad prospects for the development of forensic expertise in general.

Many of the drawbacks of post-mortem imaging are outweighed by the benefits of the method, such as reduced examination times, increased sensitivity and the fact that the body remains undisturbed. As a result, some authors believe that a significant percentage of cases of full-open-body autopsy can be avoided by using post-mortem imaging and targeted biopsy, significantly increasing the accuracy of cause of death determination.

However, the information gathered in this review shows that further research is needed. A thorough validation of this approach for use in forensic medical examination will significantly increase the prevalence of minimally invasive or non-invasive techniques, which, in combination with targeted biopsy and post-mortem angiography, could replace traditional manual autopsy.

Acknowledgements: The authors would like to thank the Kazakhstan Center for Internal Programs for funding this work as part of the Bolashaq International Scholarship Scheme, as well as the Kazakhstan Ministry of Justice for their continued support.

Compliance with Ethical Standards

- **Funding:** This work was funded by the Kazakhstan Center for International Programs through the Bolashaq International Scholarship Scheme. The funding source had no involvement in the study design; in the collection, analysis and interpretation of data; in the writing of the report; or in the decision to submit the article for publication.
- **Conflicts of interest/Competing interests:** The authors declare that they have no conflict of interest.
- **Research involving Human Participants and/or Animals:** As a review article, this study did not require the use of Human and/or animal participants

- **Informed Consent:** This article does not include any content for which informed consent would need to be obtained.

References

1. Eriksson A (2016) Forensic Pathology. In: Freeman MD, Zeegers MP (eds) Forensic Epidemiology. Academic Press, pp 151-177. doi:10.1016/b978-0-12-404584-2.00006-9
2. Filograna L, Pugliese L, Muto M, Tatulli D, Guglielmi G, Thali MJ, Floris R (2019) A Practical Guide to Virtual Autopsy: Why, When and How. *Semin Ultrasound CT MR* 40 (1):56-66. doi:10.1053/j.sult.2018.10.011
3. Michael J, Thali RD, Peter Vock (2009) The Virtopsy Approach - 3D Optical and Radiological Scanning and Reconstruction in Forensic Medicine. U.S.
4. Armao D, Semelka RC, Elias J, Jr. (2012) Radiology's ethical responsibility for healthcare reform: tempering the overutilization of medical imaging and trimming down a heavyweight. *J Magn Reson Imaging* 35 (3):512-517. doi:10.1002/jmri.23530
5. Beckmann EC (2006) CT scanning the early days. *Br J Radiol* 79 (937):5-8. doi:10.1259/bjr/29444122
6. Lauterbur PC (1973) Image formation by induced local interactions: Examples employing nuclear magnetic resonance. *Nature* 242 (5394):190-191. doi:10.1038/242190a0
7. Oliver WR, Boxwala A, Rosenman J, Cullip T, Symon J, Wagner G (1997) Three-dimensional visualization and image processing in the evaluation of patterned injuries. The AFIP/UNC experience in the Rodney King case. *Am J Forensic Med Pathol* 18 (1):1-10. doi:10.1097/00000433-199703000-00001
8. Pollanen MS, Woodford N (2013) Virtual autopsy: time for a clinical trial. *Forensic Sci Med Pathol* 9 (3):427-428. doi:10.1007/s12024-013-9408-8
9. Thali MJ, Braun M, Kneubuehl BP, Brueschweiler W, Vock P, Dirnhofer R (2000) Improved Vision in Forensic Documentation: Forensic, 3-D/CAD-supported Photogrammetry of bodily injury external surfaces, combined with Volumetric Radiologic Scanning of bodily injury internal structures, provides more investigative leads and stronger forensic evidence. In: Oliver WR (ed) 28th Aipr Workshop: 3d Visualization for Data Exploration and Decision Making, vol 3905. Proceedings of the Society of Photo-Optical Instrumentation Engineers (Spie). pp 213-221. doi:10.1117/12.384876
10. Jeffery AJ, Ruttly GN, Robinson C, Morgan B (2008) Computed tomography of projectile injuries. *Clin Radiol* 63 (10):1160-1166. doi:10.1016/j.crad.2008.03.003
11. Brough AL, Morgan B, Ruttly GN (2015) Postmortem computed tomography (PMCT) and disaster victim identification. *Radiol Med* 120 (9):866-873. doi:10.1007/s11547-015-0556-7
12. Brough AL, Morgan B, Ruttly GN (2015) The basics of disaster victim identification. *J Forensic Radiol Imaging* 3 (1):29-37. doi:10.1016/j.jofri.2015.01.002
13. Blau S, Robertson S, Johnstone M (2008) Disaster victim identification: new applications for postmortem computed tomography. *J Forensic Sci* 53 (4):956-961. doi:10.1111/j.1556-4029.2008.00742.x
14. Hounsfield GN (1980) Computed medical imaging. *Science* 210 (4465):22-28. doi:10.1126/science.6997993
15. Chakraborty S, Nakielny RA (2002) The role of spiral computed tomography (sCT) in diagnosis of acute abdomen. *Surgery (Oxford)* 20 (10):i-ii. doi:10.1383/surg.20.10.0.14403
16. Alves AM, Picoli FF, Silveira RJ, Rodrigues LG, Lenharo SLR, Silva RF, Franco A (2020) When forensic radiology meets ballistics – in vivo bullet profiling with computed tomography and autopsy validation: A case report. *Forensic Imaging* 20:200357. doi:10.1016/j.fri.2020.200357
17. Daly B, Abboud S, Ali Z, Sliker C, Fowler D (2013) Comparison of whole-body post mortem 3D CT and autopsy evaluation in accidental blunt force traumatic death using the

- abbreviated injury scale classification. *Forensic Sci Int* 225 (1-3):20-26.
doi:10.1016/j.forsciint.2012.08.006
18. Garetier M, Deloire L, Dedouit F, Dumoussat E, Saccardy C, Ben Salem D (2017) Postmortem computed tomography findings in suicide victims. *Diagn Interv Imaging* 98 (2):101-112. doi:10.1016/j.diii.2016.06.023
19. Moskala A, Wozniak K, Kluza P, Romaszko K, Lopatin O (2016) The importance of post-mortem computed tomography (PMCT) in confrontation with conventional forensic autopsy of victims of motorcycle accidents. *Leg Med (Tokyo)* 18:25-30.
doi:10.1016/j.legalmed.2015.11.005
20. Roberts ISD, Benamore RE, Benbow EW, Lee SH, Harris JN, Jackson A, Mallett S, Patankar T, Peebles C, Roobottom C, Traill ZC (2012) Post-mortem imaging as an alternative to autopsy in the diagnosis of adult deaths: a validation study. *Lancet* 379 (9811):136-142.
doi:10.1016/S0140-6736(11)61483-9
21. Jatava S (2004) Multislice CT : A quantum leap in whole body imaging. *Indian J Radiol Imaging* 14 (2):209-216
22. Rydberg J, Buckwalter KA, Caldemeyer KS, Phillips MD, Conces DJ, Jr., Aisen AM, Persohn SA, Kopecky KK (2000) Multisection CT: scanning techniques and clinical applications. *Radiographics* 20 (6):1787-1806. doi:10.1148/radiographics.20.6.g00nv071787
23. Schneider A, Feussner H (2017) Chapter 5 - Diagnostic Procedures. In: *Biomedical Engineering in Gastrointestinal Surgery*. Academic Press, pp 87-220.
doi:<https://doi.org/10.1016/B978-0-12-803230-5.00005-1>.
24. Schuijf JD, Delgado V, van Werkhoven JM, de Graaf FR, van Velzen JE, Boogers MM, Kroft LJ, de Roos A, Jukema JW, Reiber JHC, van der Wall EE, Bax JJ (2009) Novel clinical applications of state-of-the-art multi-slice computed tomography. *Int J Cardiovasc Imaging* 25 (S2):241-254. doi:10.1007/s10554-009-9422-9
25. Smith APT, Traill ZC, Roberts ISD (2018) Post-mortem imaging in adults. *Diagn Histopathol* 24 (9):365-371. doi:10.1016/j.mpdhp.2018.07.004
26. Grabherr S, Gygas E, Sollberger B, Ross S, Oesterhelweg L, Bolliger S, Christe A, Djonov V, Thali MJ, Dirnhofer R (2008) Two-step postmortem angiography with a modified heart-lung machine: preliminary results. *AJR Am J Roentgenol* 190 (2):345-351. doi:10.2214/AJR.07.2261
27. Qian H, Shao Y, Li Z, Huang P, Zou D, Liu N, Chen Y, Wan L (2016) Diagnosis of a cerebral arteriovenous malformation using isolated brain computed tomography angiography: Case report. *Am J Forensic Med Pathol* 37 (3):201-204. doi:10.1097/PAF.0000000000000247
28. Heinemann A, Vogel H, Heller M, Tzikas A, Puschel K (2015) Investigation of medical intervention with fatal outcome: the impact of post-mortem CT and CT angiography. *Radiol Med* 120 (9):835-845. doi:10.1007/s11547-015-0574-5
29. Rashid SN, Bouwer H, O'Donnell C (2012) Lethal hemorrhage from a ureteric-arterial-enteric fistula diagnosed by postmortem CT angiography. *Forensic Sci Med Pathol* 8 (4):430-435. doi:10.1007/s12024-012-9332-3
30. Turillazzi E, Frati P, Pascale N, Pomara C, Grilli G, Viola RV, Fineschi V (2016) Multi-phase post-mortem CT-angiography: a pathologic correlation study on cardiovascular sudden death. *J Geriatr Cardiol* 13 (10):855-865. doi:10.11909/j.issn.1671-5411.2016.10.003
31. Grabherr S, Grimm J, Dominguez A, Vanhaebost J, Mangin P (2014) Advances in post-mortem CT-angiography. *Br J Radiol* 87 (1036):20130488. doi:10.1259/bjr.20130488
32. Savall F, Dedouit F, Mokrane FZ, Rouge D, Saint-Martin P, Telmon N (2015) An unusual homicidal stab wound of the cervical spinal cord: A single case examined by post-mortem computed tomography angiography (PMCTA). *Forensic Sci Int* 254:e18-21.
doi:10.1016/j.forsciint.2015.06.025
33. Roberts IS, Benamore RE, Peebles C, Roobottom C, Traill ZC (2011) Technical report: diagnosis of coronary artery disease using minimally invasive autopsy: evaluation of a novel method of post-mortem coronary CT angiography. *Clin Radiol* 66 (7):645-650.
doi:10.1016/j.crad.2011.01.007

34. Saunders SL, Morgan B, Raj V, Robinson CE, Ruttly GN (2011) Targeted post-mortem computed tomography cardiac angiography: proof of concept. *Int J Legal Med* 125 (4):609-616. doi:10.1007/s00414-011-0559-4
35. Chainchel Singh MK, Abdul Rashid SN, Abdul Hamid S, Mahmood MS, Feng SS, Mohd Nawawi H, Omar E (2020) Correlation and assessment of coronary artery luminal stenosis: Post-mortem computed tomography angiogram versus histopathology. *Forensic Sci Int* 308:110171. doi:10.1016/j.forsciint.2020.110171
36. Wehrli FW (1992) The origins and future of nuclear magnetic resonance imaging. *Phys Today* 45 (6):34-42. doi:10.1063/1.881310
37. Sprawls P (2000) *Magnetic resonance imaging principles, methods and techniques*. Medical Physics Publishing Corporation, Madison, Wisconsin
38. Thali MJ, Braun M, Dirnhofer R (2003) Optical 3D surface digitizing in forensic medicine: 3D documentation of skin and bone injuries. *Forensic Sci Int* 137 (2-3):203-208. doi:10.1016/j.forsciint.2003.07.009
39. Goldman RJ, Salcido R (2002) More than one way to measure a wound: An overview of tools and techniques. *Adv Skin Wound Care* 15 (5):236-243
40. Buck U, Naether S, Braun M, Bolliger S, Friederich H, Jackowski C, Aghayev E, Christe A, Vock P, Dirnhofer R, Thali MJ (2007) Application of 3D documentation and geometric reconstruction methods in traffic accident analysis: With high resolution surface scanning, radiological MSCT/MRI scanning and real data based animation. *Forensic Sci Int* 170 (1):20-28. doi:10.1016/j.forsciint.2006.08.024
41. Thali MJ, Braun M, Brüscheweiler W, Dirnhofer R (2000) Matching tire tracks on the head using forensic photogrammetry. *Forensic Sci Int* 113 (1-3):281-287. doi:10.1016/s0379-0738(00)00234-6
42. Thali MJ, Braun M, Brueschweiler W, Dirnhofer R (2003) 'Morphological imprint': determination of the injury-causing weapon from the wound morphology using forensic 3D/CAD-supported photogrammetry. *Forensic Sci Int* 132 (3):177-181. doi:10.1016/s0379-0738(03)00021-5
43. Brüscheweiler W, Braun M, Dirnhofer R, Thali MJ (2003) Analysis of patterned injuries and injury-causing instruments with forensic 3D/CAD supported photogrammetry (FPHG): an instruction manual for the documentation process. *Forensic Sci Int* 132 (2):130-138. doi:10.1016/s0379-0738(03)00006-9
44. Martins FAR, García-Bermejo JG, Casanova EZ, Perán González JR (2005) Automated 3D surface scanning based on CAD model. *Mechatronics* 15 (7):837-857. doi:10.1016/j.mechatronics.2005.01.004
45. Shamata A, Thompson T (2018) Using structured light three-dimensional surface scanning on living individuals: Key considerations and best practice for forensic medicine. *J Forensic Leg Med* 55:58-64. doi:10.1016/j.jflm.2018.02.017
46. Aalders MC, Adolphi NL, Daly B, Davis GG, de Boer HH, Decker SJ, Dempers JJ, Ford J, Gerrard CY, Hatch GM, Hofman PAM, Iino M, Jacobsen C, Klein WM, Kubat B, Leth PM, Mazuchowski EL, Nolte KB, O'Donnell C, Thali MJ, van Rijn RR, Wozniak K (2017) Research in forensic radiology and imaging; Identifying the most important issues. *J Forensic Radiol Imaging* 8:1-8. doi:10.1016/j.jofri.2017.01.004
47. Sansoni G, Trebeschi M, Docchio F (2009) State-of-The-Art and Applications of 3D Imaging Sensors in Industry, Cultural Heritage, Medicine, and Criminal Investigation. *Sensors (Basel)* 9 (1):568-601. doi:10.3390/s90100568
48. Fais P, Giraudo C, Viero A, Miotto D, Bortolotti F, Tagliaro F, Montisci M, Cecchetto G (2016) Micro computed tomography features of laryngeal fractures in a case of fatal manual strangulation. *Leg Med (Tokyo)* 18:85-89. doi:10.1016/j.legalmed.2016.01.001
49. Wittschieber D, Beck L, Vieth V, Hahnemann ML (2016) The role of 3DCT for the evaluation of chop injuries in clinical forensic medicine. *Forensic Sci Int* 266:e59-e63. doi:10.1016/j.forsciint.2016.05.025

50. Ebert LC, Ptacek W, Naether S, Furst M, Ross S, Buck U, Weber S, Thali M (2010) Virtobot--a multi-functional robotic system for 3D surface scanning and automatic post mortem biopsy. *Int J Med Robot* 6 (1):18-27. doi:10.1002/rcs.285
51. Ebert LC, Ptacek W, Breitbeck R, Furst M, Kronreif G, Martinez RM, Thali M, Flach PM (2014) Virtobot 2.0: the future of automated surface documentation and CT-guided needle placement in forensic medicine. *Forensic Sci Med Pathol* 10 (2):179-186. doi:10.1007/s12024-013-9520-9
52. Shokry DA, Hussein MN, Hassan FM, Heinemann A, Vogel H, Puschel K (2018) Diagnostic value of multiphase postmortem computed tomography angiography in selected cases of blunt traumatic deaths. *Leg Med (Tokyo)* 34:1-6. doi:10.1016/j.legalmed.2018.07.001
53. Wijetunga C, O'Donnell C, So TY, Varma D, Cameron P, Burke M, Basset R, Smith K, Beck B (2020) Injury detection in traumatic death: Postmortem computed tomography vs. open autopsy. *Forensic Imaging* 20:100349. doi:10.1016/j.jofri.2019.100349
54. Jalalzadeh H, Giannakopoulos GF, Berger FH, Fronczek J, van de Goot FRW, Reijnders UJ, Zuidema WP (2015) Post-mortem imaging compared with autopsy in trauma victims--A systematic review. *Forensic Sci Int* 257:29-48. doi:10.1016/j.forsciint.2015.07.026
55. Cavaignac E, Savall F, Chantalat E, Faruch M, Reina N, Chiron P, Telmon N (2017) Geometric morphometric analysis reveals age-related differences in the distal femur of Europeans. *J Exp Orthop* 4 (1):21. doi:10.1186/s40634-017-0095-3
56. Carmona M, Tzioupis C, LiArno S, Faizan A, Argenson JN, Ollivier M (2019) Upper femur anatomy depends on age and gender: A three-dimensional computed tomography comparative bone morphometric analysis of 628 healthy patients' hips. *J Arthroplasty* 34 (10):2487-2493. doi:10.1016/j.arth.2019.05.036
57. Lottering N, Reynolds MS, MacGregor DM, Meredith M, Gregory LS (2014) Morphometric modelling of ageing in the human pubic symphysis: sexual dimorphism in an Australian population. *Forensic Sci Int* 236:195 e191-111. doi:10.1016/j.forsciint.2013.12.041
58. Monum T, Makino Y, Prasitwattanaseree S, Yajima D, Chiba F, Torimitsu S, Hoshioka Y, Yoshida M, Urabe S, Oya Y, Iwase H (2020) Age estimation from ossification of sternum and true ribs using 3D post-mortem CT images in a Japanese population. *Leg Med (Tokyo)* 43:101663. doi:10.1016/j.legalmed.2019.101663
59. Coty JB, Nedelcu C, Yahya S, Dupont V, Rouge-Maillart C, Verschoore M, Ridereau Zins C, Aube C (2018) Burned bodies: post-mortem computed tomography, an essential tool for modern forensic medicine. *Insights Imaging* 9 (5):731-743. doi:10.1007/s13244-018-0633-2
60. Thali MJ, Yen K, Plattner T, Schweitzer W, Vock P, Ozdoba C, Dirnhofer R (2002) Charred body: Virtual autopsy with multi-slice computed tomography and magnetic resonance imaging. *J Forensic Sci* 47 (6):1326-1331
61. Franco A, Thevissen P, Coudyzer W, Develter W, Van de Voorde W, Oyen R, Vandermeulen D, Jacobs R, Willems G (2013) Feasibility and validation of virtual autopsy for dental identification using the Interpol dental codes. *J Forensic Leg Med* 20 (4):248-254. doi:10.1016/j.jflm.2012.09.021
62. Leth PM, Madsen BH (2017) Drowning investigated by post mortem computed tomography and autopsy. *J Forensic Radiol Imaging* 9:28-30. doi:10.1016/j.jofri.2017.02.002
63. Kawasumi Y, Kawabata T, Sugai Y, Usui A, Hosokai Y, Sato M, Saito H, Ishibashi T, Hayashizaki Y, Funayama M (2013) Diagnosis of drowning using post-mortem computed tomography based on the volume and density of fluid accumulation in the maxillary and sphenoid sinuses. *Eur J Radiol* 82 (10):e562-566. doi:10.1016/j.ejrad.2013.06.015
64. Bolliger SA, Ross S, Marino L, Thali MJ, Schweitzer W (2015) Shell fragment aspiration seen at post-mortem computed tomography indicating drowning. *J Forensic Radiol Imaging* 3 (1):87-90. doi:10.1016/j.jofri.2014.12.005
65. Levy AD, Abbott RM, Mallak CT, Getz JM, Harcke HT, Champion HR, Pearse LA (2006) Virtual autopsy: preliminary experience in high-velocity gunshot wound victims. *Radiology* 240 (2):522-528. doi:10.1148/radiol.2402050972

66. Thali MJ, Jackowski C, Oesterhelweg L, Ross SG, Dirnhofer R (2007) VIRTOPSY - the Swiss virtual autopsy approach. *Leg Med (Tokyo)* 9 (2):100-104. doi:10.1016/j.legalmed.2006.11.011
67. Arthurs OJ, Hutchinson JC, Sebire NJ (2017) Current issues in postmortem imaging of perinatal and forensic childhood deaths. *Forensic Sci Med Pathol* 13 (1):58-66. doi:10.1007/s12024-016-9821-x
68. Asao R, Nishida K, Goto H, Goto Y, Ichiba N, Ohsawa I (2020) Postmortem computed tomography of gas gangrene with aortic gas in a dialysis patient. *CEN Case Rep*. doi:10.1007/s13730-020-00456-y
69. Baumeister R, Gauthier S, Schweitzer W, Thali MJ, Mauf S (2016) Small – but fatal: Postmortem computed tomography indicated acute tonsillitis. *J Forensic Radiol Imaging* 6:52-56. doi:10.1016/j.jofri.2015.11.008
70. Chatzaraki V, Bolliger SA, Thali MJ, Eggert S, Ruder TD (2017) Unexpected brain finding in pre-autopsy postmortem CT. *Forensic Sci Med Pathol* 13 (3):367-371. doi:10.1007/s12024-017-9880-7
71. Fryer EP, Traill ZC, Benamore RE, Roberts IS (2013) High risk medicolegal autopsies: is a full postmortem examination necessary? *J Clin Pathol* 66 (1):1-7. doi:10.1136/jclinpath-2012-201137
72. Noriki S, Kinoshita K, Inai K, Sakai T, Kimura H, Yamauchi T, Iwano M, Naiki H (2017) Newly recognized cerebral infarctions on postmortem imaging: a report of three cases with systemic infectious disease. *BMC Med Imaging* 17 (1):4. doi:10.1186/s12880-016-0174-4
73. Jackowski C, Dirnhofer S, Thali M, Aghayev E, Dirnhofer R, Sonnenschein M (2005) Postmortem diagnostics using MSCT and MRI of a lethal streptococcus group A infection at infancy: a case report. *Forensic Sci Int* 151 (2-3):157-163. doi:10.1016/j.forsciint.2005.01.015
74. Linnau KF, Cohen WA (2002) Radiologic evaluation of attempted suicide by hanging: cricotracheal separation and common carotid artery dissection. *AJR Am J Roentgenol* 178 (1):214. doi:10.2214/ajr.178.1.1780214
75. Abdul Rashid SN, Martinez RM, Ampanozi G, Thali MJ, Bartsch C (2013) A rare case of suicide by gunshot with nasal entry assessed by classical autopsy, post-mortem computed tomography (PMCT) and post-mortem magnetic resonance imaging (PMMR). *J Forensic Radiol Imaging* 1 (2):63-67. doi:10.1016/j.jofri.2013.03.044
76. Leth PM, Struckmann H, Lauritsen J (2013) Interobserver agreement of the injury diagnoses obtained by postmortem computed tomography of traffic fatality victims and a comparison with autopsy results. *Forensic Sci Int* 225 (1-3):15-19. doi:10.1016/j.forsciint.2012.03.028
77. Grabherr S, Baumann P, Minoiu C, Fahrni S, Mangin P (2016) Post-mortem imaging in forensic investigations: current utility, limitations, and ongoing developments. *Research and Reports in Forensic Medical Science*:25. doi:10.2147/rrfms.s93974
78. Katada K (2002) Characteristics of multislice CT. *Jpn Med Assoc J* 45 (4):175-179
79. Aljerian K, Alhawas A, Alqahtani S, Golding B, Alkahtani T (2015) First virtual autopsy in Saudi Arabia: A case report with literature review. *J Forensic Radiol Imaging* 3 (1):76-79. doi:10.1016/j.jofri.2014.11.002
80. Filleron T (2018) Comparing sensitivity and specificity of medical imaging tests when verification bias is present: The concept of relative diagnostic accuracy. *Eur J Radiol* 98:32-35. doi:10.1016/j.ejrad.2017.10.022
81. Simons D, Sassenberg A, Schlemmer HP, Yen K (2014) Forensic imaging for causal investigation of death. *Korean J Radiol* 15 (2):205-209. doi:10.3348/kjr.2014.15.2.205
82. Ampanozi G, Flach PM, Fornaro J, Ross SG, Schweitzer W, Thali MJ, Ruder TD (2015) Systematic analysis of the radiologic findings of aortic dissections on unenhanced postmortem computed tomography. *Forensic Sci Med Pathol* 11 (2):162-167. doi:10.1007/s12024-015-9654-z

83. Eriksson A, Gustafsson T, Hoistad M, Hultcrantz M, Jacobson S, Mejare I, Persson A (2017) Diagnostic accuracy of postmortem imaging vs autopsy-A systematic review. *Eur J Radiol* 89:249-269. doi:10.1016/j.ejrad.2016.08.003
84. Scholing M, Saltzherr TP, Fung Kon Jin PH, Ponsen KJ, Reitsma JB, Lameris JS, Goslings JC (2009) The value of postmortem computed tomography as an alternative for autopsy in trauma victims: a systematic review. *Eur Radiol* 19 (10):2333-2341. doi:10.1007/s00330-009-1440-4
85. Ampanozi G, Halbheer D, Ebert LC, Thali MJ, Held U (2020) Postmortem imaging findings and cause of death determination compared with autopsy: a systematic review of diagnostic test accuracy and meta-analysis. *Int J Legal Med* 134 (1):321-337. doi:10.1007/s00414-019-02140-y
86. Roberts IS, Benbow EW, Bisset R, Jenkins JP, Lee SH, Reid H, Jackson A (2003) Accuracy of magnetic resonance imaging in determining cause of sudden death in adults: comparison with conventional autopsy. *Histopathology* 42 (5):424-430. doi:10.1046/j.1365-2559.2003.01614.x
87. Can cross-sectional imaging as an adjunct and/or alternative to the invasive autopsy be implemented within the NHS? (2012). NHS Implementation Sub-Group of the Department of Health Post Mortem Forensic and Disaster Imaging Group,
88. Aghayev E, Yen K, Sonnenschein M, Ozdoba C, Thali M, Jackowski C, Dirnhofer R (2004) Virtopsy post-mortem multi-slice computed tomography (MSCT) and magnetic resonance imaging (MRI) demonstrating descending tonsillar herniation: comparison to clinical studies. *Neuroradiology* 46 (7):559-564. doi:10.1007/s00234-004-1212-4
89. Underwood J (2012) Post-mortem imaging and autopsy: rivals or allies? *Lancet* 379 (9811):100-102. doi:10.1016/s0140-6736(11)61584-5