



## King's Research Portal

DOI:

[10.1016/j.neuroimage.2017.01.047](https://doi.org/10.1016/j.neuroimage.2017.01.047)

*Document Version*

Other version

[Link to publication record in King's Research Portal](#)

*Citation for published version (APA):*

Keunen, K., Counsell, S. J., & Benders, M. J. (2017). The emergence of functional architecture during early brain development. *NeuroImage*. Advance online publication. <https://doi.org/10.1016/j.neuroimage.2017.01.047>

### **Citing this paper**

Please note that where the full-text provided on King's Research Portal is the Author Accepted Manuscript or Post-Print version this may differ from the final Published version. If citing, it is advised that you check and use the publisher's definitive version for pagination, volume/issue, and date of publication details. And where the final published version is provided on the Research Portal, if citing you are again advised to check the publisher's website for any subsequent corrections.

### **General rights**

Copyright and moral rights for the publications made accessible in the Research Portal are retained by the authors and/or other copyright owners and it is a condition of accessing publications that users recognize and abide by the legal requirements associated with these rights.

- Users may download and print one copy of any publication from the Research Portal for the purpose of private study or research.
- You may not further distribute the material or use it for any profit-making activity or commercial gain
- You may freely distribute the URL identifying the publication in the Research Portal

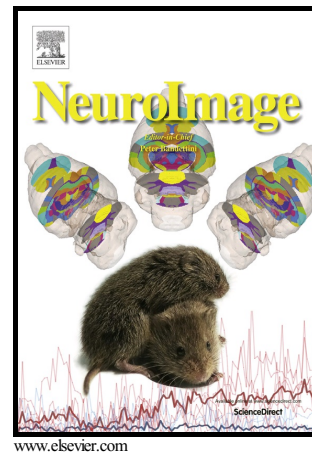
### **Take down policy**

If you believe that this document breaches copyright please contact [librarypure@kcl.ac.uk](mailto:librarypure@kcl.ac.uk) providing details, and we will remove access to the work immediately and investigate your claim.

# Author's Accepted Manuscript

The emergence of functional architecture during early brain development

Kristin Keunen, Serena J Counsell, Manon J Benders



PII: S1053-8119(17)30054-X

DOI: <http://dx.doi.org/10.1016/j.neuroimage.2017.01.047>

Reference: YNIMG13751

To appear in: *NeuroImage*

Received date: 31 August 2016

Revised date: 22 December 2016

Accepted date: 18 January 2017

Cite this article as: Kristin Keunen, Serena J Counsell and Manon J Benders, The emergence of functional architecture during early brain development *NeuroImage*, <http://dx.doi.org/10.1016/j.neuroimage.2017.01.047>

This is a PDF file of an unedited manuscript that has been accepted for publication. As a service to our customers we are providing this early version of the manuscript. The manuscript will undergo copyediting, typesetting, and a review of the resulting galley proof before it is published in its final citable form. Please note that during the production process errors may be discovered which could affect the content, and all legal disclaimers that apply to the journal pertain

**The emergence of functional architecture during early brain development**

Kristin Keunen<sup>a,b</sup>, Serena J Counsell<sup>c</sup>, Manon J Benders<sup>a,b\*</sup>

<sup>a</sup>. Department of Neonatology, Division Woman and Baby, University Medical Center

Utrecht, Lundlaan 6, P.O. box 85090, 3508 AB Utrecht, Netherlands

<sup>b</sup>. Brain Center Rudolf Magnus, University Medical Center Utrecht, Universiteitsweg 100,  
3584 CG Utrecht, Netherlands

<sup>c</sup>. Centre for the Developing Brain, Division of Imaging Sciences & Biomedical Engineering,  
King's College London, St Thomas Hospital, London, SE1 7EH, United Kingdom

\* **Corresponding author.** Manon J Benders, MD PhD, Department of Neonatology, Division  
Woman and Baby, University Medical Center Utrecht, KE 04.123.1, PO Box 85090, 3508  
AB Utrecht, Netherlands. m.benders@umcutrecht.nl

**Abstract**

Early human brain development constitutes a sequence of intricate processes resulting in the ontogeny of functionally operative neural circuits. Developmental trajectories of early brain network formation are genetically programmed and can be modified by epigenetic and environmental influences. Such alterations may exert profound effects on neurodevelopment, potentially persisting throughout the lifespan. This review focuses on the critical period of fetal and early postnatal brain development. Here we collate findings from neuroimaging studies, with a particular focus on functional MRI research that interrogated early brain network development in both health and high-risk or disease states. First, we will provide an overview of the developmental processes that take place from the embryonic period through early infancy in order to contextualize brain network formation. Second, functional brain network development in the typically developing brain will be discussed. Third, we will touch on prenatal and perinatal risk factors that may interfere with the trajectories of functional brain wiring, including prenatal substance exposure, maternal mental illness and preterm birth. Collectively, studies have revealed the blueprint of adult human brain organization to be

pcw = postconceptional weeks

present in the neonatal brain. Distinct attributes of human brain architecture have even been detected in the developing fetal brain from as early as 24 postconceptional weeks. During postnatal brain development, the brain's wiring pattern is further sculpted and modulated to become the full facsimile of the adult human brain, with functional brain network refinement being more rigorous than structural brain network maturation. Advances in neuroimaging techniques have paved the way towards a comprehensive understanding of the maturational pathways of brain network development and of *how* early developmental adversity may affect these trajectories. Such insights are fundamental for our understanding of human brain functioning, for early identification of infants at risk, as well as for future neuroprotective strategies.

**Keywords**

functional MRI, brain networks, neonatal, fetal, connectivity

**Introduction**

The human brain is arguably the most complex system in biology and yet its macroscopic layout is nearly complete by the time of term birth. The neonatal cerebral cortex displays a complex, adult-like gyrification pattern and in the underlying white matter all large-scale connections are already in place (Ball et al., 2014; Lodygensky et al., 2010; Stiles and Jernigan, 2010; Takahashi et al., 2012; van den Heuvel et al., 2014). Historically, much of what we know about the intricate processes of early brain development came from post mortem studies in human fetuses, neonates, and non-human primates (Flechsig, 1920; Goldman-Rakic, 1987; Innocenti and Price, 2005; Kostovic, 2002; LaMantia and Rakic, 1990). With the increasing availability of high-quality neuroimaging techniques, including anatomical sequences customized to the developing neonatal and fetal brain, diffusion weighted imaging (DWI) and functional MRI, as well as electrophysiology recordings

including electroencephalography (EEG), it has now become feasible to study early human brain development in unprecedented detail *in vivo* (Ball et al., 2014; Counsell et al., 2007; Fransson et al., 2007; Huppi et al., 1998; Maas et al., 2004; Omidvarnia et al., 2014; Partridge et al., 2004; Smyser et al., 2001; Thomason et al., 2013; Toulmin et al., 2015; van den Heuvel et al., 2014). These advances have led to exciting new insights into both healthy and atypical macroscale brain network development and have paved the way to bridge the gap between the brain's neurobiological architecture and its behavioral repertoire. Such cross-correlation studies are invaluable for improving our understanding of *how* and *when* neural circuit establishment supports cognitive function and increasingly complex behavior.

Given that many psychiatric and neurological disorders may have a neurodevelopmental origin, mapping the brain's anatomical and functional trajectories is crucial for early identification of altered development (Gao et al., 2016). These disturbances in brain development may be genetically programmed, epigenetically mediated or environmentally influenced and early detection may provide a window of opportunity for preventive strategies.

The present review aims to consolidate recent findings from prenatal and neonatal brain network studies that have helped move the field forward, with a focus on the ontogeny of functional brain network architecture. Many techniques are currently available to study functional brain connectivity, including EEG, magnetoencephalography (MEG), functional near-infrared spectroscopy (NIRS), and task-related functional MRI (Arichi et al., 2013; Farroni et al., 2013; Omidvarnia et al., 2014) (see for review of the most commonly employed techniques (Lowe et al., 2016)); however this review will primarily address resting state functional connectivity studies. Resting state functional MRI (rs-fMRI) employs spontaneous fluctuations in blood oxygen level dependent (BOLD) signal at low frequencies (0.01-0.1 Hz)

across the entire brain at a millimeters' resolution. Brain regions are considered functionally connected if they display synchronous activity, i.e. if their temporal fluctuations in BOLD signal are highly correlated (Biswal et al., 1995).

The first section of this review comprises a general overview of the major processes delineating prenatal and early postnatal brain development in order to provide a conceptual framework to build on. Developmental processes are compared against MRI and EEG correlates as illustrated in Figure 1. The second section represents a summary of functional connectivity studies examining healthy early development of functional brain network architecture. In the third section, we will discuss neuroimaging findings of deviating brain network development that occurs as a result of identifiable risk, including prenatal exposure to substances, maternal mental illness and preterm birth. Fourth, we will touch on important methodological considerations that specifically apply to imaging fetal and infant populations. Finally, we will present our conclusions based on the collated findings and discuss the remaining gaps that deserve attention for future research.

## **Developmental processes underlying early brain network formation**

### ***Embryonic and early fetal period***

The human brain comprises 86 billion neurons and an even more staggering number of synapses, dendrites, axons and glia cells connecting and supporting them (Azevedo et al., 2009). The vast majority of these cells are formed during prenatal development (Webb et al., 2001). The brain originates from the anterior portion of the neural tube (Bystron et al., 2008; Gilbert, 2000). Following neurulation (i.e. closure of the neural tube), which starts at embryonic day 21 and is finished by day 27 (Bystron et al., 2008; Stiles and Jernigan, 2010), the precursor of the human brain rapidly expands and undergoes a series of processes including proliferation, neurogenesis and differentiation, orchestrated by an intricate genetic

program (Bystron et al., 2008; Stiles and Jernigan, 2010; Webb et al., 2001). By mid-gestation neurogenesis is largely complete (Stiles and Jernigan, 2010) and during this phase, i.e. between the third and fifth month of gestation, neuronal migration peaks with the first neurons appearing in the cortical plate by 15 postconceptional weeks (PCW) (Bystron et al., 2008; Webb et al., 2001) (Figure 1). Once neurons have reached their destination in the cortical plate, they start extending axons and dendrites (Webb et al., 2001). Early afferent fibers appear from as early as 8-10 PCW forming the cerebral stalk at the level of the thalamus (Vasung et al., 2010). High field DWI studies have demonstrated the emergence of projection- and commissural fibers, including the internal capsule and corpus callosum from as early as 13 and 15 PCW respectively (Huang et al., 2009; Takahashi et al., 2012) (Figure 2).

### ***Midfetal period***

The second trimester of pregnancy is characterized by exuberant synaptogenesis, dendritic sprouting and axonal path finding and thus by neural circuit formation, thereby setting the stage for functional communication (Webb et al., 2001). Thalamocortical and cortico-thalamic fibers form transient circuits with subplate neurons before growing into the developing cortex and thalamus respectively (Kostovic and Jovanov-Milosevic, 2006; Volpe, 2009). The subplate is located below the cortical plate and serves as a 'waiting' compartment for afferent fibers. During the waiting period, which lasts approximately four weeks, afferents receive instructive input and start projecting onto their cortical targets. Concurrently, the corpus callosum extends in an anterior to posterior fashion (Huang et al., 2009, 2006), first synapsing on neurons in the transient subplate zone before establishing its definitive connections in the cortical plate (Kostovic and Jovanov-Milosevic, 2006; Volpe, 2009). Once thalamocortical connections are established, which has been noted to occur between 24-32

PCW (Figure 2), sensory stimuli including visual and auditory input can reach the developing cortex (Kostovic and Jovanov-Milosevic, 2006). The formation of transient thalamocortical-subplate circuits has been linked to the emergence of *spontaneous activity transients* (SATs) on electroencephalography recordings in extremely preterm infants (Kostovic and Jovanov-Milosevic, 2006; Vanhatalo and Kaila, 2006). SATs are endogenous bursts of neuronal activity, which are either autonomously generated in the cortex, or in response to input from the subplate and are thought to drive neural circuit formation before sensory stimuli come online (Tolonen et al., 2007; Vanhatalo and Kaila, 2006). Conversely, sensory driven activity is thought to be reflected in *ongoing cortical activity*, which gradually increases with advancing postconceptional age and reaches fully continuous levels by 45-50 PCW (Tolonen et al., 2007; Vanhatalo and Kaila, 2006) (Figure 1).

### ***Late fetal period***

In the third trimester thalamocortical connections are consolidated, while commissural and long-range association fibers including the corpus callosum, fronto-occipital fasciculus and inferior longitudinal fasciculus leave the subplate to extend into the cortical plate (Kostovic and Jovanov-Milosevic, 2006). The notion that thalamocortical connectivity is established by the time of birth was recently illustrated in a rs-fMRI study, showing a high level of overlap between the distribution of thalamocortical projections in the thalamus in the neonatal brain and their topographical organization in the adult human brain (Toulmin et al., 2015). While axons continue to grow, facilitating major connections in the white matter to find their cortical targets, the overlying cortex transforms its relatively smooth surface into a highly convoluted mantle with secondary and tertiary sulci that resembles the adult human brain (Stiles and Jernigan, 2010; Striedter et al., 2014). MRI studies in preterm infants have reported a five-fold increase in cortical surface area and doubling of cortical curvature

measures in the timeframe that coincides with the third trimester of pregnancy (Ajayi-Obe et al., 2000; Dubois et al., 2008; Kapellou et al., 2006; Moeskops et al., 2015).

Concomitantly, a number of processes take place that extend well into the postnatal period, including myelination, synaptogenesis and the formation of dendrites and associated dendritic spines. Myelination emerges as a result of maturation of oligodendrocytes in the white matter and progresses in a caudal to rostral, central to peripheral, and posterior to anterior fashion with brain areas involved in primary functions myelinating before association areas (Catani et al., 2013; Kinney et al., 1988; Webb et al., 2001; Welker and Patton, 2012). Mature oligodendrocytes produce myelin, forming fatty sheaths around developing axons, thereby vigorously enhancing conduction speed. White matter maturation, including axonal growth, increasing axonal coherence and myelination can be clearly delineated using DWI (Braga et al., 2015; Geng et al., 2012; Hagmann et al., 2010; Huppi et al., 1998; Partridge et al., 2004; Sadeghi et al., 2013).

### ***Postnatal brain development***

With all major white matter tracts being in place by the end of normal gestation, it is not surprising that structural connectome studies - examining whole brain connectivity on a macroscopic level (Box 1) - have revealed structural network organization in the neonatal brain to show great similarity to the adult human brain (Ball et al., 2014; Brown et al., 2014; Ratnarajah et al., 2013; Shi et al., 2012; Tymofiyeva et al., 2012; van den Heuvel et al., 2014; Yap et al., 2011). Key features of adult connectome architecture have been demonstrated in the neonatal brain, including a *small world* organization - combining local specialization with long-range efficiency -, a *modular* topology - meaning that the network constitutes smaller subnetworks for specialized information processing -, and a heavy tailed *degree* distribution with brain regions which show the highest number of connections forming a central core or

'rich club' (Box 1). A number of these studies included preterm subjects and preterm birth is known to impact on brain development, with potentially detrimental effects on brain network architecture, which will be discussed in the third section of this review. However, alterations in the global framework of brain wiring have not been observed and are unlikely in the absence of major brain lesions (Bütefisch, 2004). The adverse effects of preterm birth have predominantly been noted to affect the quality of connections rather than their overall layout (Ball et al., 2015, 2014, 2013; Doria et al., 2010a; Scheinost et al., 2015; Smyser et al., 2010; Toulmin et al., 2015).

Whilst macroscale white matter connections have been established and long-range inter- and intrahemispheric projections are no longer formed in the early postnatal brain, short-range cortico-cortical connections continue to develop and have been traced through the fourth month after birth (Burkhalter, 1993). The postnatal period is further marked by refinement of existing intracortical connections, ongoing dendritic arborization and an explosive increase in synaptogenesis, eventually resulting in an abundance of connections (Huttenlocher and Courten de, 1987; Huttenlocher and Dabholkar, 1997; Innocenti and Price, 2005; Kostovic and Jovanov-Milosevic, 2006; Stiles and Jernigan, 2010). Overproduction of synapses and associated dendrites and axons is observed across all mammalian species and is followed by pruning (i.e. selective elimination of connections) (Bianchi et al., 2013; Innocenti and Price, 2005). The latter process spans childhood and adolescence and occurs as a result of competition for neurotrophic factors including brain-derived neurotrophic factor (BDNF) and the need for afferent input to stabilize immature, labile connections (Hua and Smith, 2004; Innocenti and Price, 2005; Stiles and Jernigan, 2010; Webb et al., 2001).

A number of DWI studies have evaluated postnatal structural brain network development (Hagmann et al., 2012, 2010; Huang et al., 2013; Tymofiyeva et al., 2013; Yap et al., 2011) and demonstrated increasing integration and decreasing segregation (or

*clustering*, Box 1) as hallmark features of childhood connectome maturation. Similarly, modules become increasingly interconnected and are further shaped, especially in the earliest postnatal years (Hagmann et al., 2010; Huang et al., 2013). Yet, major reorganization of their configuration has not been observed (Hagmann et al., 2010). Consistent with the persistence of the modular configuration in the developing postnatal brain, the localization of *hub nodes* (i.e. brain regions that take up a central position in the network) has been noted to remain largely stable (Hagmann et al., 2012; Huang et al., 2013).

Although present-day findings of neuroimaging *in vivo* cannot be directly translated to microscopic neural circuit development, not least because of the substantial gap in spatial scale on which macro- and microscale brain network development take place, there are considerable similarities in the biological principles that both systems seem to adhere to (Scholtens et al., 2014; van den Heuvel et al., 2014). Myelination and increases in axonal diameter of white matter connections promote efficiency of axonal information transfer and may therefore be reflected in increasing integration capacity of the macroscale connectome. Decreasing clustering may be the macroscopic representation of pruning, leading to modulation of the network from a relatively 'random' topology to a specialized organization, maintaining and stabilizing meaningful connections.

### **Functional network development**

The past decade has witnessed a rapid surge of interest in rs-fMRI as an imaging technique to investigate functional connectivity in the earliest stages of human development. The first paper on the presence of functional brain networks in the neonatal brain was published in 2007 (Fransson et al., 2007) and a number of research groups have now committed to the challenging task of functional imaging *in utero* (Ferrazzi et al., 2014; Schöpf et al., 2012; Seshamani et al., 2014; Thomason et al., 2013). Collectively, these efforts have led to exciting

insights into functional brain network architecture in the earliest phases following its emergence. As such, these findings have furthered our understanding of functional network development in the typically developing brain and may prove invaluable for early identification of infants at risk of neurodevelopmental disorders. In what follows, we will collate findings from functional connectivity studies during healthy fetal and neonatal brain development.

Interhemispheric connectivity has been investigated in the fetal brain from as early as 24 PCW and has been noted to increase with advancing gestational age, following a medial to lateral trajectory (Thomason et al., 2013). Similarly, long-range thalamocortical and intrahemispheric connectivity are also strengthened with increasing fetal age (24-39 PCW) (Thomason et al., 2015) (Figure 1).

Fetal imaging is challenging due to motion of the fetus and surrounding tissues because of maternal respiration, requiring specific acquisition and analysis frameworks for this population (Ferrazzi et al., 2014; Seshamani et al., 2014). Furthermore, image resolution and signal-to-noise ratio are frequently reduced compared to that acquired in postnatal fMRI. Collectively, these differences impact the comparability of fetal and infant studies and are therefore relevant for their interpretation, which will be further elaborated in the final section of this review.

A number of studies have focused on the emergence of resting-state networks in fetuses and newborn infants (Alcauter et al., 2015a; Arichi et al., 2010; Fransson et al., 2009, 2007, Gao et al., 2014a, 2014b, 2013, 2009; Lin et al., 2008; Schöpf et al., 2012; Smyser et al., 2010; Thomason et al., 2015). In healthy adults, a distinct set of resting-state networks has been described encompassing brain regions involved in primary functions (i.e. sensorimotor, auditory and visual processing network), and higher-order functions including self-awareness,

memory, attention and executive functioning (Damoiseaux et al., 2006; Smith et al., 2009). Networks engaged in complex cognitive functioning are spatially distributed across the cortex, typically spanning multiple brain regions. In contrast, resting state networks governing primary functions tend to be more localized with their functional connections mainly limited to homologous counterparts (Damoiseaux et al., 2006; Fox et al., 2005; Raichle et al., 2001; Smith et al., 2009).

Comparable functional network architecture has been revealed in the neonatal brain, albeit in an immature state (Doria et al., 2010a; Fransson et al., 2009; Gao et al., 2014a, 2014b, 2013, 2009; Lin et al., 2008; Smyser et al., 2010) (Figure 3). Primary networks can be clearly depicted in newborn infants and display a mature configuration whilst higher-order networks are largely fragmented (Doria et al., 2010a; Fransson et al., 2009; Gao et al., 2014a, 2014b; Smyser et al., 2010). These higher order networks are merely restricted to their core regions in the newborn brain, exhibiting relatively limited functional connections with spatially distant homologues. The default mode network for instance - that has been associated with self-awareness, future planning, mind wandering and conceiving the perspectives of others ('theory of mind') in healthy adult brain functioning -, extends the posterior cingulate cortex, ventral and dorsal medial prefrontal cortex, inferior parietal lobule, lateral temporal cortex and the hippocampus regions in the adult human brain (Buckner et al., 2008; Buckner and Carroll, 2007; Raichle et al., 2001). In neonates, the default mode network is immature and incomplete, encompassing frontal and association cortices including the medial prefrontal cortex and posterior cingulate cortex (Doria et al., 2010a; Gao et al., 2014a, 2009; Smyser et al., 2010) (Figure 4). A fragmented precursor of the default mode network, comprising the medial prefrontal cortex and posterior cingulate cortex, was recently also identified in the developing fetal brain from 35 PCW (Thomason et al., 2015).

In line with the primary-to-higher-order maturational sequence of functional networks, immature forms of the sensorimotor, visual and auditory network have been detected from an earlier gestational age, i.e. approximately 30 PCW in healthy fetuses (n=32) (Thomason et al., 2015). A recent study elegantly mapped the maturational trajectories of resting state networks in the first postnatal year at three-month intervals in 65 typically developing infants (Gao et al., 2014a). The sensorimotor network, visual processing network and auditory/language network demonstrated adult-like topology at birth and showed minimal topological changes during the first postnatal year. The dorsal attention network and default mode network followed the development of primary networks and became increasingly synchronized with spatially remote within-network brain regions, exhibiting mature topology at one year of age. Higher order cognitive networks, including the salience network and bilateral frontoparietal networks - involved in executive control, decision-making and working memory - were noted to mature latest and still displayed an incomplete configuration at the end of the first postnatal year (Gao et al., 2014a, 2014b).

Interestingly, not only does the maturational sequence of functional resting state networks mimic the developmental pattern of myelination and synaptogenesis, it also parallels the order in which behavioral functions are achieved. Developmental milestones in visual and sensorimotor function are most prominent in the first postnatal year, when their corresponding functional brain networks are complete (Adams et al., 2004; WHO Multicentre Growth Reference Study Group, 2006). Conversely, higher order cognitive functions such as executive control and social cognition develop well into adolescence and early adulthood (Casey et al., 2000). Their associated brain networks become operational last.

### ***Functional connectivity and behavioral counterparts***

Although the developmental trajectories of resting state networks and neurodevelopmental milestones display remarkable similarities, cross-correlation studies linking findings on functional networks to behavioral measures during early development are sparse (Alcauter et al., 2015b, 2014). A longitudinal study assessing functional brain network development and their cognitive correlates in 74 infants found functional connectivity between the thalamus and the immature salience network at age one year to be associated with working memory performance at age two (Alcauter et al., 2014).

Much of our present-day knowledge about brain-behavior relationships shortly after birth comes from task-based fMRI studies (Allievi et al., 2016; Anderson et al., 2001; Arichi et al., 2013, 2012, 2010; Born et al., 1996; Dehaene-Lambertz et al., 2010, 2006, 2002; Erberich et al., 2006; Heep et al., 2009; Konishi et al., 2002; Morita et al., 2000). These studies have provided important background on the brain's responses to sensory input during the earliest phases of development of brain-behavior interactions. Adult-like activation patterns were observed in response to a variety of sensory stimuli, including tactile and proprioceptive stimulation (passive hand movement) (Arichi et al., 2012, 2010; Erberich et al., 2006), auditory (Anderson et al., 2001), olfactory (the odor of infant formula) (Arichi et al., 2013) and visual input. fMRI studies in two- to three-month-old infants demonstrated left-lateralized activation of perisylvian regions including the superior temporal gyrus, angular gyrus and Broca's area in response to native-language speech (Dehaene-Lambertz et al., 2006, 2002). The response followed a hierarchical pattern, with auditory regions being activated first, followed by superior temporal regions and the temporal poles and Broca's area in the inferior frontal cortex; a pattern that is highly consistent with language organization in the mature brain. Excitingly, the infant brain seemed capable of distinguishing speech from music and exhibited signs of early learning. Music induced activation of bilateral auditory areas (posterior temporal regions), while speech showed a left-hemispheric preference.

Furthermore, listening to the mother's voice resulted in differently modulated responses in both language and emotion areas than when infants were exposed to a stranger's voice (Dehaene-Lambertz et al., 2010).

Together, these findings point towards the early existence of functionally operable brain networks that are genetically dictated and sculpted by environmental input and learning. The observation of brain activity in language areas including Broca's area well before the onset of produced speech, further underscores the complex interplay between brain and behavior during development, which is continuously modified by environmental and (epi)genetic influences. Further studies are required to improve our understanding of these brain-behavior relationships.

### ***Functional connectome***

A number of reports described functional network architecture in neonates on a whole-brain level (De Asis-Cruz et al., 2015; Fransson et al., 2011; Gao et al., 2011). In line with network attributes of the neonatal structural connectome and adult human brain organization, functional brain networks in newborn infants exhibit *small-world* topology, a *modular* organization and a heavy-tailed *degree* distribution with functional *hubs* (Box 1). A recent MRI study in the developing preterm brain observed substantial overlap between structural and functional brain network organization in 17 neonates (van den Heuvel et al., 2014). Given the small sample size and that preterm infants are at considerable risk of neurodevelopmental deficits, further studies are required that extend these investigations to the healthy term-born infant brain.

Differences between neonates and adults have also been noted. Functional hubs were found to be predominantly confined to brain regions supporting primary functions (e.g. sensorimotor and visual cortex) and only a few hubs have been observed in association

cortices including the insula and posterior cingulate cortex (De Asis-Cruz et al., 2015; Fransson et al., 2011; Gao et al., 2011). Notably, the configuration of functional brain hubs as observed in the neonatal brain is highly consistent with the outline of resting state networks during this period.

Whole-brain network topology has also been examined in the prenatal period, with a focus on modularity. In a pioneering study including 33 pregnant women, fetal brain network architecture demonstrated a modular decomposition, which was more pronounced in younger fetuses (24-31 PCW) compared with older fetuses (31-39 PCW). These findings suggest functional brain wiring to become increasingly integrated during prenatal development (Thomason et al., 2014).

### ***Electrophysiological connectivity***

Brain activity, which can be measured using EEG is considered crucial for consolidation of immature neural circuits and therefore plays a pivotal role in early brain network formation. A number of studies have explored functional connectivity patterns of early electrical brain activity as extracted from EEG recordings. The neonatal brain displayed a marked bimodal connectivity pattern, characterized by strong functional coupling of spatially remote brain regions during periods of high levels of brain activity (mostly reflecting SATs) and minimal functional synchrony during periods of relative quiescence (low amplitude bands). This bimodality is thought to govern early functional brain wiring and diminishes with advancing postnatal age, when young neurons mature and endogenous brain activity (SATs) is progressively replaced by sensory driven oscillations (*ongoing cortical activity*) (Omidvarnia et al., 2014). Other prominent features of neonatal brain activity encompass distinct differences between sleep states, well before the onset of mature sleep-wake EEG

representations and highly dynamic signature patterns of functional neural synchrony that mature rapidly during the first few postnatal weeks (Tokariev et al., 2015).

In summary, the rapid and complex ontogeny of structural brain wiring during the second and third trimester of human gestation facilitates functional neural circuit establishment. The emergence of long-range projection, commissural and association fibers initiates the onset of thalamocortical, as well as inter- and intrahemispheric functional connectivity. These early functional connections are consolidated by SATs, which are crucial for survival and maturation of neurons shortly after their genesis. In line with the notion that early electrical brain activity is fundamental for the establishment of operational neural circuits, a recent study in 21 preterm infants revealed early endogenous brain activity as measured during the first three postnatal days to be positively related to brain growth between 30 and 40 postmenstrual weeks. Strongest associations were demonstrated with deep gray matter structures (Benders et al., 2014).

Present-day neuroimaging studies have detected functional brain networks from as early as 26 PCW (Ferrazzi et al., 2014; Thomason et al., 2015). These networks follow a primary-to-higher order maturational sequence, consistent with their behavioral correlates. By the time of term birth, primary networks including the systems involved in visual, auditory and sensorimotor functioning are largely complete, while higher order networks display fragmented, immature connectivity patterns. The notion that the blueprint of functional brain network organization is present in the neonatal brain is emulated by whole-brain connectome findings, which have revealed adult-like network attributes including *small-world* organization, *modularity* and a *rich club* of high degree *hub* nodes, although this early connectome architecture is similarly immature. Crucial first steps have been taken toward improving our understanding of the cognitive and behavioral implications of early functional

brain wiring. Significant caveats remain that deserve attention from the field. Moreover, longitudinal studies are required to answer important questions regarding developmental trajectories of healthy functional network formation.

### **Prenatal and perinatal risk factors affecting functional network development**

Risk factors for altered functional network development include environmental and epigenetic risk, such as prenatal drug exposure, maternal mental illness and preterm birth. Although these conditions and risk factors are of different origin, their common denominator is that they exert effects in the earliest stages of human brain development, potentially permanently altering the developmental pathways of neural circuit formation. Behavioral sequelae are observed across myriad domains, including academic achievement, executive functioning, attention, conduct and social-emotional skills from childhood throughout the lifespan.

Connectivity studies have begun to take on the challenge of mapping developmental trajectories in the earliest phases of human life, when the brain is most plastic and modifiable, and are paving the way towards an understanding of how prenatal and perinatal risk alter these trajectories. In this section, we will provide an overview of the growing literature on the impact of identifiable risk on the formation of functional brain organization and touch on the mechanisms underlying these effects.

#### ***Prenatal drug exposure***

Prenatal exposure to both licit and illicit substances is a major public health concern. In the US, prevalence estimates of illegal drug use during pregnancy vary between 4.4 - 5.1% (Behnke and Smith, 2013). Self-reported legal substance use is even more prevalent, with 16.3% of pregnant women reporting cigarette smoking and 10.8% disclosing alcohol consumption (Behnke and Smith, 2013). Prenatal substance exposure may elicit teratogenic

effects in the embryonic stage. During fetal development, substances may affect the developing brain in a number of direct and indirect ways. Psychoactive drugs and nicotine target monoaminergic neurotransmitter systems, including dopamine, epinephrine and serotonin signaling, thereby modifying the intricate orchestration of neural circuit establishment. Other neural processes susceptible to substance exposure include neural proliferation and migration, axonal growth and dendritic branching. Fetal brain development may be indirectly affected by reduced oxygen and nutrient supply as a result of placental and/or umbilical vasoconstriction. Additionally, substance abuse is frequently associated with poor maternal health and nutrition, which may further compromise the developing fetus (Ross et al., 2015).

Until recently, the impact of maternal substance use on early brain wiring - i.e. before significant environmental influences come into play - remained largely unexplored. Two studies investigated the effects of prenatal exposure to cocaine and marijuana on functional connectivity in the neonatal brain using a well-controlled design (Grewen, 2015; Salzwedel et al., 2016, 2015). In the first study, that evaluated 45 cocaine-exposed neonates with or without *in utero* exposure to other substances, including marijuana, opioids, alcohol, nicotine and serotonin reuptake inhibitors (SSRIs), 43 newborn infants exposed to the latter substances without cocaine and 64 drug-naive control infants, cocaine-specific alterations were observed in functional connectivity strength between the amygdala and medial prefrontal cortex and between the thalamus and anterior cortex regions (Salzwedel et al., 2016, 2015). The amygdala, insula and thalamus were preselected as regions of interest, because of their involvement in reward- and control systems, and because of high levels of dopamine expression in the thalamus. The second study was performed in a subset (n=63) of this sample, with a focus on marijuana. Marijuana exposure was associated with disrupted

connectivity of caudate and insula seed regions; brain structures that are known to display high expression levels of the type 1 cannabinoid receptor (Grewen, 2015). Furthermore, diffuse patterns of both hyper- and hypoconnectivity were observed between the insula, amygdala and thalamus seeds and widespread cortical areas including medial frontal cortices, sensorimotor regions and the medial visual cortex in the presence of unspecific prenatal drug exposure, as compared to unexposed neonates (Grewen, 2015; Salzwedel et al., 2016, 2015).

### ***Maternal mental illness***

Maternal mental health disorders may affect the establishment of neural circuits in the developing brain owing to maternal genetic risk factors, alterations in the intrauterine environment (e.g. increased cortisol levels or exposure to disease related medication) and environmental risk including low socio-economic status, poor nutrition and prenatal substance exposure. Confounding factors pose a particular challenge to disentangling hereditary susceptibility that may be conferred to the developing fetus *in utero* from environmental factors that may be versatile or that conversely may enhance risk.

Maternal depression (and related SSRI use) has been associated with disturbances in brain connectivity of newborn infants across a number of imaging modalities. A small rs-fMRI study in six-month old infants (n=24) reported stronger functional connectivity of the amygdala seed region with distributed brain areas of the limbic system and medial prefrontal cortex when their mothers had reported more severe depressive symptoms during the second trimester of pregnancy. Details on maternal psychoactive drug use that may have influenced the observed effects were not reported (Qiu et al., 2015). A recent DWI study described widespread reductions in white matter microstructural maturation of predominantly corticofugal and corticothalamic projection fibers in 20 newborn infants of depressed mothers who had used SSRIs during pregnancy compared to healthy matched control infants. These

alterations were not observed in neonates born to depressed mothers who had not been exposed to SSRIs (Jha et al., 2016). Complementing this literature, a recent study reported both local and global changes in EEG recordings of 22 neonates prenatally exposed to SSRIs because of maternal mood- or anxiety disorder. These alterations persisted beyond the acute withdrawal period and were noted to be independent of the underlying maternal mental condition. Abnormalities included lower interhemispheric synchronicity and shorter interburst intervals (i.e. periods of relative rest in brain activity) during quiet sleep and lower cross-frequency integration during active sleep, the latter indicating reduced coordination of oscillations from spatially linked neural networks (e.g. the subplate and cortex) (Videman et al., 2016).

Taken together, these findings suggest that SSRI use in pregnant women with mood disorders affects early brain wiring in the developing fetus, although evidence remains scarce and heterogeneous at present. The unique contribution of maternal depression to these perturbations remains poorly understood. Future research of longitudinal design is thus needed to determine whether maternal mood disorders and related drug therapy (SSRIs) have distinct neural substrates and to monitor if the observed deviances are persistent.

To our knowledge only one study has investigated the impact of maternal schizophrenia on neonatal brain network organization. The authors reported distributed changes in structural covariance networks of the cortex - based on synchronous variation in cortical morphology measures as derived from structural MRI - in 26 neonates born to mothers with schizophrenia or schizoaffective disorder, whereas the structural connectome of white matter connections was largely unaffected. Alterations in structural covariance were related to the brain's overall communication capacity, including reduced global efficiency, longer connection distance and less hub nodes and edges in high-risk infants (Shi et al., 2012).

To date, the influence of maternal schizophrenia on early-life *functional* connectivity remains to be elucidated.

### ***Preterm birth***

Preterm birth occurs at a developmental time when crucial processes of neural circuit formation are taking place, including synaptogenesis, axonal growth and late neuronal migration (Volpe, 2009). Besides the event of preterm birth itself posing substantial risk to the establishment of healthy and fully operational brain network organization, prematurity is frequently accompanied by postnatal illness that may amplify the detrimental effects on early brain wiring. Not surprisingly, preterm birth is associated with impaired brain development reflected in reduced brain volumes, diminished cortical gyrification and delayed maturation of gray and white matter structures (Ball et al., 2012; Keunen et al., 2012; Rathbone et al., 2011; Shimony et al., 2016; Volpe, 2009). These deficits are also present in the absence of focal brain injury and have been noted to persist through childhood (Counsell et al., 2008; Fischigómez et al., 2015; Monson et al., 2016). Behavioral sequelae of these structural disturbances in brain development are observed across a wide spectrum of neurodevelopmental outcomes and include cognitive delay, working memory impairment, learning disabilities, executive functioning deficits, internalizing and externalizing behavioral problems and developmental psychopathology including autism and attention deficit hyperactivity disorder (Fischigómez et al., 2015; Johnson et al., 2010, 2009; Monson et al., 2016; Urban et al., 2015).

Accumulating literature converges on pervasively disrupted thalamocortical connectivity as a result of preterm birth. Both structural (Ball et al., 2016, 2015, 2013) and functional deficits (Doria et al., 2010a; Smyser et al., 2010; Toulmin et al., 2015) have been reported. Disturbances in *structural* connectivity were revealed to be most widespread, involving thalamocortical connections distributed across frontal, temporal, occipital and

parietal lobes (Ball et al., 2016, 2013). Complementing these findings, reduced structural connectivity between the thalamus and extensive cortical regions as measured at term equivalent age was found to be related to poorer cognitive performance at age two years in 57 preterm born children (Ball et al., 2015). The neurobehavioral link as observed in the latter study, has stressed the profoundly disruptive effects of preterm birth on brain wiring for the first time.

Two studies have charted the development of resting state networks in the preterm brain evaluating 74 (Doria et al., 2010a) and 100 datasets respectively (Smyser et al., 2010). Consistent with findings in typically developing infants, primary functional networks appeared first, followed by precursors of higher order networks. A number of developmental algorithms that seemed to dictate resting state network genesis could be identified. These rules included medial to lateral expansion of interhemispheric functional connectivity, strengthening of interhemispheric connectivity before anteroposterior intrahemispheric connectivity, increasing within-network coherence and progression from diffuse, yet spatially proximate connectivity patterns to focused local connectivity with emerging connections to spatially distant regions.

Facsimiles of these developmental patterns were observed in a recent EEG study. EEG recordings were obtained in 20 preterm infants between 30 and 44 weeks postmenstrual age and revealed strong increases in interhemispheric synchrony and less pronounced increases in intrahemispheric connectivity. In addition, anterior brain regions showed stronger synchrony compared with posterior brain regions and most subjects displayed higher correlations within the left hemisphere than the right, suggesting an anteroposterior maturation gradient and early left lateralization (Koolen et al., 2016).

Differences between preterm infants and healthy full-term neonates were also noted in numerous reports and were predominantly confined to the strength of connections. Preterm

infants exhibited reduced interhemispheric connectivity (Smyser et al., 2013, 2010) and impaired lateralization of language areas (Kwon et al., 2015). Resting state networks as observed in typically developing neonates were present in preterm infants scanned at term equivalent age, yet displayed reductions in connectivity strength of primarily higher order networks (Doria et al., 2010b; Smyser et al., 2016). Similarly, on a whole brain level hallmark network attributes including *small world* organization, *modularity* and *rich club* architecture were found to be preserved while differences were revealed in the quality of connections (Scheinost et al., 2015). A recent functional connectome study observed reductions in *clustering* and *rich club* connectivity in 12 preterm infants at term equivalent age compared with 25 full-term controls (Scheinost et al., 2015). Conversely, in a DWI study of structural whole-brain connectivity (46 preterm infants and 17 healthy term controls), prematurity was associated with relatively intact *rich-club* organization but altered cortical-subcortical connectivity and short-distance connections outside the core network (Ball et al., 2014). Contrasting findings may be the result of methodological, clinical and technical differences.

Finally, the impact of white matter injury resulting from extensive intraventricular hemorrhage - a typical pattern of preterm brain injury (Papile et al., 1978) - on functional connectivity was investigated in two reports that employed rs-fMRI and EEG (Omidvarnia et al., 2015; Smyser et al., 2013). Both inter- and intrahemispheric functional connectivity were diminished. Evidence from the EEG study suggests widespread reductions in functional connectivity in the presence of white matter injury as well as disruptions of the bimodal connectivity pattern. The latter constitutes a distinct feature of healthy early brain development (Omidvarnia et al., 2015).

Collectively, these findings consolidate previous research on the impact of preterm birth on early brain development and add substantially to our understanding of its neural

underpinnings. Adverse effects of prematurity have been revealed to predominantly target thalamocortical connectivity, with major implications for long-term cognitive functioning and behavior. Given the developmental processes of thalamocortical axonal pathfinding that peak during the period of (extremely) preterm birth, these widespread disruptions and their ongoing adversity are intuitive (Volpe, 2009). In parallel, reductions in interhemispheric and long-range intrahemispheric connectivity strength have repeatedly been reported, indicating comparable impact on the functionality of commissural and association fibers. On a global level these disturbances seem to affect communication capacity, while the overall layout of resting state networks and functional whole-brain network architecture appears to remain intact.

### **Methodological considerations**

There are a number of technical concerns that need to be taken into consideration when interpreting rs-fMRI and DWI data. Important topics include false positives, false negatives, test-retest reliability and acquisition protocols (de Reus and van den Heuvel, 2013; Eklund et al., 2016; Glasser et al., 2016; Zuo and Xing, 2014). However, an in-depth discussion of these methodological considerations falls beyond the scope of this review. Here, we will highlight some of the key methodological concerns that specifically apply to fetal and neonatal neuroimaging, particularly focusing on issues regarding rs-fMRI.

Head motion is of particular concern in fetal and neonatal neuroimaging. Most infants are scanned during natural sleep or after administering mild sedation (25-60 mg/kg oral chloral hydrate) (Doria et al., 2010a; Toulmin et al., 2015; van den Heuvel et al., 2014) and although appropriate measures are generally taken to reduce motion artifacts including feeding and swaddling (where infants are scanned during natural sleep), wrapping the infant in a vacuum fixation pillow and applying hearing protection devices to reduce exposure to

acoustic noise, even subtle head movement remains a significant problem. Furthermore, the use of sedative medication - if administered - is generally confined to infants scanned in a clinical setting and may thus introduce a bias in terms of the effect of motion, as well as differences in physiological parameters and sleep state/level of consciousness between health and disease states. Preventing motion is even more challenging in fetal imaging, where large displacements of the fetal head are not uncommon and maternal respiration and potential movement present additional challenges (Ferrazzi et al., 2014).

Head motion introduces spurious, yet systematic noise into rs-fMRI data, reducing long-range connectivity between distant brain regions (primarily along anterior-posterior and vertical axes) and increasing the strength of functional correlations between nearby voxels in the brain (predominantly left-right connectivity) (Power et al., 2012; van Dijk et al., 2012). Worryingly, these structured motion artifacts coincide with reported developmental effects: young children display a segregated communication framework, with strong connections between approximating brain regions and relatively limited long-range connectivity. Over the course of development, the brain modulates its layout and enhances long-range connections while diminishing local connectivity (Collin and van den Heuvel, 2013; Power et al., 2010). Hence, efforts to disentangle developmental effects from noise are vitally important in any rs-fMRI preprocessing pipeline. Evaluating motion (e.g. using frame-wise displacement or DVARS (Derivative of Root-mean-square VARiance over voxels) and incorporating strategies to account for motion artifacts that go beyond rigid body realignment and regression of motion parameters are required (Laumann et al., 2016; Power et al., 2015; Satterthwaite et al., 2013). Data censoring or scrubbing, i.e. removal of motion-contaminated data, which has been proposed by a number of research groups, may be particularly appealing for fetal and infant imaging and has been applied to most present-day rs-fMRI datasets (i.e. publications from ~ 2013 and beyond). However, concerns have also been raised about

temporal concatenation of non-consecutive time-points and how such approaches may affect the data as well as about how excessive data removal may impact correlations between time-series (Gao et al., 2016; Power et al., 2015). Analysis strategies designed specifically to accommodate fetal movement by addressing motion on a slice-by-slice timescale and correcting for signal variations due to changes in the position of the fetal head with respect to the receiver coil are now available and enable most (potentially all) of the acquired rs-fMRI data to be retained (Ferrazzi et al., 2014).

Another relevant aspect that limits correlations between studies of early development is the use of different atlases for rs-fMRI data registration. Some studies employ adult templates (Alcauter et al., 2015a, 2014, Gao et al., 2011, 2009, Salzwedel et al., 2016, 2015) whereas others adopt group-level clustering to design a population-specific template based on similarity between voxels (Scheinost et al., 2015; Thomason et al., 2014, 2013) or make use of available neonatal atlases (e.g. (Oishi et al., 2012)). Manual region of interest (ROI) placement is also performed in a number of resting-state network studies (Doria et al., 2010a; Smyser et al., 2010; Thomason et al., 2015). Altogether, optimization and standardization of the preprocessing pipeline and acquisition protocols are essential to allow for reliable comparisons across study populations and enable multi-center studies to be conducted. Such efforts will form the groundwork to further our understanding of early healthy and aberrant functional brain network development.

### **Future perspectives and conclusion**

In recent years, neuroimaging research has shown that the overall framework of functional brain architecture, including functional networks and whole-brain functional connectome organization emerges in synchrony with the ontogeny of structural brain wiring during the mid through late fetal period. In the neonatal period both systems encompass the blueprint of

their adult analogues, albeit in an immature state. Postnatal trajectories of functional brain network development appear more comprehensive than maturational courses of structural brain wiring. While structural refinements revolve around improvement of communication efficiency and connection strength, functional brain architecture transforms its spatial arrangement. Functional brain hubs shift from essentially primary order brain regions to higher-order association areas during postnatal development. Accordingly, functional resting state networks mature according to principles of increasing complexity. Networks involved in primary functions are largely complete in the neonatal brain, while higher order networks display a fragmented layout in the early postnatal period and continue to mature during the postnatal phase, with networks involved in the most intricate cognitive processes being the last to mature. A comprehensive understanding of the trajectories of typical early brain wiring is fundamental to the study of disrupted connectivity, and although crucial steps have been taken, further work is required. Additional studies of longitudinal design would be of particular relevance, as well as research linking functional brain network organization to cognitive and behavioral functions that are attained later in development. Such studies may help identify relevant imaging biomarkers.

Functional connectivity studies have begun to elucidate the impact of early developmental adversity. Preterm birth disrupts thalamocortical connectivity. Reductions in inter- and intrahemispheric connectivity have also been revealed. These widespread perturbations impair the brain's overall communication efficiency. Intrauterine exposure to psychoactive drugs seems to exert more targeted attacks, firstly confined to specific receptor-regions and secondly leading to accelerated engagement of the amygdala-prefrontal circuit. Whether maternal psychopathology intrinsically affects early brain wiring remains elusive and warrants further study.

There is an urgent need for studies investigating gene-environment interactions in relation to early brain development in both health and high-risk or disease states. Important first steps have recently been taken, cross-correlating common genetic variation analysis with DWI findings in preterm neonates (Boardman et al., 2014; Krishnan et al., 2016). These studies illustrated genes mostly involved in lipid pathways to be related to the degree of maturation of distributed white matter tracts at term equivalent age.

Functional connectivity research is on the verge of elucidating developmental trajectories of healthy early human brain organization as well as of portraying departures from these typical trajectories that may pervasively affect brain functioning. Ongoing multidisciplinary and multimodal efforts are needed to unravel the inception of complex brain wiring and to help identify windows of opportunity for future interventions for those who experience serious developmental risk during the earliest phases in life.

#### **Funding sources**

K. Keunen is supported by a grant from the Wilhelmina Children's Hospital Research Fund (Vrienden WKZ) to M.P. van den Heuvel. Professor S.J. Counsell is supported by the Medical Research Council (UK) (grant nos: MR/K006355/1 and MR/LO11530/1), and the Department of Health via the National Institute for Health Research (NIHR) Comprehensive Biomedical Research Centre award to Guy's and St Thomas' NHS Foundation Trust in partnership with King's College London and King's College Hospital NHS Foundation Trust.

#### **Acknowledgements**

We would like to thank Ruben Schmidt and Siemon de Lange for their valuable input on the graphical content of the manuscript.

**References**

- Adams, R., Mercer, M., Courage, M., 2004. Ontogenetic development of visual acuity over the first three postnatal years. *Ophthalmic Genet.* 25, 199–203.  
doi:10.1080/13816810490498314
- Ajayi-Obe, M., Saeed, N., Cowan, F., Rutherford, M., Edwards, A., 2000. Reduced development of cerebral cortex in extremely preterm infants. *Lancet* 356, 1162–1163.  
doi:10.1016/S0140-6736(00)02761-6
- Alcauter, S., Lin, W., Keith Smith, J., Gilmore, J.H., Gao, W., 2015a. Consistent anterior-posterior segregation of the insula during the first 2 years of life. *Cereb. Cortex* 25, 1176–1187. doi:10.1093/cercor/bht312
- Alcauter, S., Lin, W., Smith, J.K., Goldman, B.D., Reznick, J.S., Gilmore, J.H., Gao, W., 2015b. Frequency of spontaneous BOLD signal shifts during infancy and correlates with cognitive performance. *Dev. Cogn. Neurosci.* 12, 40–50. doi:10.1016/j.dcn.2014.10.004
- Alcauter, S., Lin, W., Smith, X.J.K., Short, S.J., Goldman, B.D., Reznick, J.S., Gilmore, J.H., Gao, W., 2014. Development of Thalamocortical Connectivity during Infancy and Its Cognitive Correlations. *J. Neurosci.* 34, 9067–9075. doi:10.1523/JNEUROSCI.0796-14.2014
- Allievi, A.G., Arichi, T., Tusor, N., Kimpton, J., Arulkumaran, S., Counsell, S.J., Edwards, A.D., Burdet, E., 2016. Maturation of Sensori-Motor Functional Responses in the Preterm Brain. *Cereb. Cortex* 26, 402–413. doi:10.1093/cercor/bhv203
- Anderson, A.W., Marois, R., Colson, E.R., Peterson, B.S., Duncan, C.C., Ehrenkranz, R.A., Schneider, K.C., Gore, J.C., Ment, L.R., 2001. Neonatal auditory activation detected by functional magnetic resonance imaging. *Magn. Reson. Imaging* 19, 1–5.  
doi:10.1016/S0730-725X(00)00231-9
- Arichi, T., Fagiolo, G., Varela, M., Melendez-Calderon, A., Allievi, A., Merchant, N., Tusor,

- N., Counsell, S.J., Burdet, E., Beckmann, C.F., Edwards, A.D., 2012. Development of BOLD signal hemodynamic responses in the human brain. *Neuroimage* 63, 663–673. doi:10.1016/j.neuroimage.2012.06.054
- Arichi, T., Gordon-Williams, R., Allievi, A., Groves, A.M., Burdet, E., Edwards, A.D., 2013. Computer-controlled stimulation for functional magnetic resonance imaging studies of the neonatal olfactory system. *Acta Paediatr. Int. J. Paediatr.* 102, 868–875. doi:10.1111/apa.12327
- Arichi, T., Moraux, A., Melendez, A., Doria, V., Groppo, M., Merchant, N., Combs, S., Burdet, E., Larkman, D.J., Counsell, S.J., Beckmann, C.F., Edwards, A.D., 2010. Somatosensory cortical activation identified by functional MRI in preterm and term infants. *Neuroimage* 49, 2063–2071. doi:10.1016/j.neuroimage.2009.10.038
- Azevedo, F.A.C., Carvalho, L.R.B., Grinberg, L.T., Farfel, J.M., Ferretti, R.E.L., Leite, R.E.P., Filho, W.J., Lent, R., Herculano-Houzel, S., 2009. Equal numbers of neuronal and nonneuronal cells make the human brain an isometrically scaled-up primate brain. *J. Comp. Neurol.* 513, 532–541. doi:10.1002/cne.21974
- Ball, G., Aljabar, P., Arichi, T., Tusor, N., Cox, D., Merchant, N., Nongena, P., Hajnal, J. V., Edwards, A.D., Counsell, S.J., 2016. NeuroImage Machine-learning to characterise neonatal functional connectivity in the preterm brain. *Neuroimage* 124, 267–275. doi:10.1016/j.neuroimage.2015.08.055
- Ball, G., Aljabar, P., Zebari, S., Tusor, N., Arichi, T., Merchant, N., Robinson, E.C., Ogundipe, E., Rueckert, D., Edwards, A.D., Counsell, S.J., 2014. Rich-club organization of the newborn human brain. *Proc. Natl. Acad. Sci. U. S. A.* 111, 7456–61. doi:10.1073/pnas.1324118111
- Ball, G., Boardman, J.P., Aljabar, P., Pandit, A., Arichi, T., Merchant, N., Rueckert, D., Edwards, A.D., Counsell, S.J., 2013. The influence of preterm birth on the developing

- thalamocortical connectome. *Cortex* 49, 1711–1721. doi:10.1016/j.cortex.2012.07.006
- Ball, G., Boardman, J.P., Rueckert, D., Aljabar, P., Arichi, T., Merchant, N., Gousias, I.S., Edwards, A.D., Counsell, S.J., 2012. The effect of preterm birth on thalamic and cortical development. *Cereb. Cortex* 22, 1016–1024. doi:10.1093/cercor/bhr176
- Ball, G., Pazderova, L., Chew, A., Tusor, N., Merchant, N., Arichi, T., Allsop, J.M., Cowan, F.M., Edwards, A.D., Counsell, S.J., 2015. Thalamocortical connectivity predicts cognition in children born preterm. *Cereb. Cortex* 25, 4310–4318. doi:10.1093/cercor/bhu331
- Behnke, M., Smith, V.C., 2013. Prenatal Substance Abuse: Short- and Long-term Effects on the Exposed Fetus. *Pediatrics* 131, e1009–e1024. doi:10.1542/peds.2012-3931
- Benders, M.J., Palmu, K., Menache, C., Borradori-Tolsa, C., Lazeyras, F., Sizonenko, S., Dubois, J., Vanhatalo, S., Hüppi, P.S., 2014. Early Brain Activity Relates to Subsequent Brain Growth in Premature Infants. *Cereb. Cortex* 1–11. doi:10.1093/cercor/bhu097
- Bianchi, S., Stimpson, C.D., Duka, T., Larsen, M.D., Janssen, W.G.M., Collins, Z., Bauernfeind, A.L., Schapiro, S.J., Baze, W.B., McArthur, M.J., Hopkins, W.D., Wildman, D.E., Lipovich, L., Kuzawa, C.W., Jacobs, B., Hof, P.R., Sherwood, C.C., 2013. Synaptogenesis and development of pyramidal neuron dendritic morphology in the chimpanzee neocortex resembles humans. *Proc. Natl. Acad. Sci. U. S. A.* 110 Suppl, 10395–401. doi:10.1073/pnas.1301224110
- Biswal, B., Yetkin, F., Haughton, V., Hyde, J., 1995. Functional connectivity in the motor cortex of resting human brain using echo-planar MRI. *Magn. Reson. Med.* 34, 537–541.
- Boardman, J.P., Walley, A., Ball, G., Takousis, P., Krishnan, M.L., Hughes-Carre, L., Aljabar, P., Serag, A., King, C., Merchant, N., Srinivasan, L., Froguel, P., Hajnal, J., Rueckert, D., Counsell, S., Edwards, A.D., 2014. Common Genetic Variants and Risk of Brain Injury After Preterm Birth. *Pediatrics* 133, e1655–e1663. doi:10.1542/peds.2013-

3011

- Born, P., Rostrup, E., Leth, H., Peitersen, B., Lou, H.C., 1996. Change of visually induced cortical activation patterns during development. *Lancet* 347, 543. doi:10.1016/S0140-6736(96)91175-7
- Braga, R.M., Roze, E., Ball, G., Merchant, N., Tusor, N., Arichi, T., Edwards, A.D., Rueckert, D., Counsell, S.J., 2015. Development of the corticospinal and callosal tracts from extremely premature birth up to 2 years of age. *PLoS One* 10, 1–15. doi:10.1371/journal.pone.0125681
- Brown, C.J., Miller, S.P., Booth, B.G., Andrews, S., Chau, V., Poskitt, K.J., Hamarneh, G., 2014. Structural network analysis of brain development in young preterm neonates. *Neuroimage* 101, 667–680. doi:10.1016/j.neuroimage.2014.07.030
- Buckner, R.L., Andrews-Hanna, J.R., Schacter, D.L., 2008. The brain's default network: Anatomy, function, and relevance to disease. *Ann. N. Y. Acad. Sci.* 1124, 1–38. doi:10.1196/annals.1440.011
- Buckner, R.L., Carroll, D.C., 2007. Self-projection and the brain. *Trends Cogn. Sci.* 11, 49–57. doi:10.1016/j.tics.2006.11.004
- Burkhalter, A., 1993. Development of forward and feedback connections between areas V1 and V2 of human visual cortex. *Cereb. Cortex* 3, 476–87.
- Bütefisch, C.M., 2004. Plasticity in the human cerebral cortex: lessons from the normal brain and from stroke. *Neuroscientist* 10, 163–173. doi:10.1177/1073858403262152
- Bystron, I., Blakemore, C., Rakic, P., 2008. Development of the human cerebral cortex: Boulder Committee revisited. *Nat. Rev. Neurosci.* 9, 110–22. doi:10.1038/nrn2252
- Casey, B.J., Giedd, J.N., Thomas, K.M., 2000. Structural and functional brain development and its relation to cognitive development. *Biol. Psychol.* 54, 241–257. doi:10.1016/S0301-0511(00)00058-2

- Catani, M., Thiebaut de Schotten, M., Slater, D., Dell'Acqua, F., 2013. Connectomic approaches before the connectome. *Neuroimage* 80, 2–13.  
doi:10.1016/j.neuroimage.2013.05.109
- Collin, G., van den Heuvel, M.P., 2013. The ontogeny of the human connectome: development and dynamic changes of brain connectivity across the life span. *Neuroscientist* 19, 616–28. doi:10.1177/1073858413503712
- Counsell, S.J., Dyet, L.E., Larkman, D.J., Nunes, R.G., Boardman, J.P., Allsop, J.M., Fitzpatrick, J., Srinivasan, L., Cowan, F.M., Hajnal, J. V., Rutherford, M.A., Edwards, A.D., 2007. Thalamo-cortical connectivity in children born preterm mapped using probabilistic magnetic resonance tractography. *Neuroimage* 34, 896–904.  
doi:10.1016/j.neuroimage.2006.09.036
- Counsell, S.J., Edwards, A.D., Chew, A.T.M., Anjari, M., Dyet, L.E., Srinivasan, L., Boardman, J.P., Allsop, J.M., Hajnal, J. V., Rutherford, M.A., Cowan, F.M., 2008. Specific relations between neurodevelopmental abilities and white matter microstructure in children born preterm. *Brain* 131, 3201–8. doi:10.1093/brain/awn268
- Damoiseaux, J.S., Rombouts, S.A.R.B., Barkhof, F., Scheltens, P., Stam, C.J., Smith, S.M., Beckmann, C.F., 2006. Consistent resting-state networks across healthy subjects. *Proc. Natl. Acad. Sci. U. S. A.* 103, 13848–53. doi:10.1073/pnas.0601417103
- De Asis-Cruz, J., Bouyssi-Kobar, M., Evangelou, I., Vezina, G., Limperopoulos, C., 2015. Functional properties of resting state networks in healthy full-term newborns. *Sci. Rep.* 5, 17755. doi:10.1038/srep17755
- de Reus, M.A., van den Heuvel, M.P., 2013. Estimating false positives and negatives in brain networks. *Neuroimage* 70, 402–409. doi:10.1016/j.neuroimage.2012.12.066
- Dehaene-Lambertz, G., Dehaene, S., Hertz-Pannier, L., 2002. Functional neuroimaging of speech perception in infants. *Science* 298, 2013–5. doi:10.1126/science.1077066

- Dehaene-Lambertz, G., Hertz-Pannier, L., Dubois, J., Meriaux, S., Roche, A., Sigman, M.,  
Dehaene, S., 2006. Functional organization of perisylvian activation during presentation  
of sentences in preverbal infants. *Proc. Natl. Acad. Sci.* 103, 14240–14245.  
doi:10.1073/pnas.0606302103
- Dehaene-Lambertz, G., Montavont, A., Jobert, A., Alliol, L., Dubois, J., Hertz-Pannier, L.,  
Dehaene, S., 2010. Language or music, mother or Mozart? Structural and environmental  
influences on infants' language networks. *Brain Lang.* 114, 53–65.  
doi:10.1016/j.bandl.2009.09.003
- Doria, V., Beckmann, C.F., Arichi, T., Merchant, N., Groppo, M., Turkheimer, F.E.,  
Counsell, S.J., Murgasova, M., Aljabar, P., Nunes, R.G., Larkman, D.J., Rees, G.,  
Edwards, A.D., 2010a. Emergence of resting state networks in the preterm human brain.  
*Proc. Natl. Acad. Sci. U. S. A.* 107, 20015–20020. doi:10.1073/pnas.1007921107
- Doria, V., Beckmann, C.F., Arichi, T., Merchant, N., Groppo, M., Turkheimer, F.E.,  
Counsell, S.J., Murgasova, M., Aljabar, P., Nunes, R.G., Larkman, D.J., Rees, G.,  
Edwards, a D., 2010b. Emergence of resting state networks in the preterm human brain.  
*Proc. Natl. Acad. Sci. U. S. A.* 107, 20015–20020. doi:10.1073/pnas.1007921107
- Dubois, J., Benders, M., Cachia, a., Lazeyras, F., Ha-Vinh Leuchter, R., Sizonenko, S. V.,  
Borradori-Tolsa, C., Mangin, J.F., Hüppi, P.S., 2008. Mapping the early cortical folding  
process in the preterm newborn brain. *Cereb. Cortex* 18, 1444–1454.  
doi:10.1093/cercor/bhm180
- Eklund, A., Nichols, T.E., Knutsson, H., 2016. Cluster failure: Why fMRI inferences for  
spatial extent have inflated false-positive rates, *Proceedings of the National Academy of  
Sciences.* doi:10.1073/pnas.1602413113
- Erberich, S.G., Panigrahy, A., Friedlich, P., Seri, I., Nelson, M.D., Gilles, F., 2006.  
Somatosensory lateralization in the newborn brain. *Neuroimage* 29, 155–161.

doi:10.1016/j.neuroimage.2005.07.024

Farroni, T., Chiarelli, A.M., Lloyd-Fox, S., Massaccesi, S., Merla, A., Di Gangi, V.,

Mattarello, T., Faraguna, D., Johnson, M.H., 2013. Infant cortex responds to other

humans from shortly after birth. *Sci. Rep.* 3, 2851. doi:10.1038/srep02851

Ferrazzi, G., Kuklisova Murgasova, M., Arichi, T., Malamateniou, C., Fox, M.J.,

Makropoulos, A., Allsop, J., Rutherford, M., Malik, S., Aljabar, P., Hajnal, J. V., 2014.

Resting State fMRI in the moving fetus: A robust framework for motion, bias field and spin history correction. *Neuroimage* 101, 555–568.

doi:10.1016/j.neuroimage.2014.06.074

Fischi-gómez, E., Vasung, L., Meskaldji, D., Lazeyras, F., Borradori-tolsa, C., Hagmann, P.,

Barisnikov, K., Thiran, J., Hüppi, P.S., 2015. Structural Brain Connectivity in School-

Age Preterm Infants Provides Evidence for Impaired Networks Relevant for Higher

Order Cognitive Skills and Social Cognition 2793–2805. doi:10.1093/cercor/bhu073

Flechsig, P., 1920. Anatomie des menschlichen Gehirns und Rückenmarks auf

myelogenetischer Grundlage. Georg Thieme.

Fox, M.D., Snyder, A.Z., Vincent, J.L., Corbetta, M., Van Essen, D.C., Raichle, M.E., 2005.

The human brain is intrinsically organized into dynamic, anticorrelated functional

networks. *Proc. Natl. Acad. Sci. U. S. A.* 102, 9673–8. doi:10.1073/pnas.0504136102

Fransson, P., Åden, U., Blennow, M., Lagercrantz, H., 2011. The functional architecture of

the infant brain as revealed by resting-state fMRI. *Cereb. Cortex* 21, 145–154.

doi:10.1093/cercor/bhq071

Fransson, P., Skiöld, B., Engström, M., Hallberg, B., Mosskin, M., Åden, U., Lagercrantz, H.,

Blennow, M., 2009. Spontaneous brain activity in the newborn brain during natural

sleep-an fMRI study in infants born at full term. *Pediatr. Res.* 66, 301–305.

doi:10.1203/PDR.0b013e3181b1bd84

- Fransson, P., Skiöld, B., Horsch, S., Nordell, A., Blennow, M., Lagercrantz, H., Aden, U., 2007. Resting-state networks in the infant brain. *Proc. Natl. Acad. Sci. U. S. A.* 104, 15531–15536. doi:10.1073/pnas.0704380104
- Gao, W., Alcauter, S., Elton, A., Hernandez-Castillo, C.R., Smith, J.K., Ramirez, J., Lin, W., 2014a. Functional Network Development During the First Year: Relative Sequence and Socioeconomic Correlations. *Cereb. cortex* 1–10. doi:10.1093/cercor/bhu088
- Gao, W., Alcauter, S., Smith, J.K., Gilmore, J.H., Lin, W., 2014b. Development of human brain cortical network architecture during infancy. *Brain Struct. Funct.* 1–14. doi:10.1007/s00429-014-0710-3
- Gao, W., Gilmore, J.H., Giovanello, K.S., Smith, J.K., Shen, D., Zhu, H., Lin, W., 2011. Temporal and spatial evolution of brain network topology during the first two years of life. *PLoS One* 6. doi:10.1371/journal.pone.0025278
- Gao, W., Gilmore, J.H., Shen, D., Smith, J.K., Zhu, H., Lin, W., 2013. The synchronization within and interaction between the default and dorsal attention networks in early infancy. *Cereb. Cortex* 23, 594–603. doi:10.1093/cercor/bhs043
- Gao, W., Lin, W., Grewen, K., Gilmore, J.H., 2016. Functional Connectivity of the Infant Human Brain : Plastic and Modifiable. doi:10.1177/1073858416635986
- Gao, W., Zhu, H., Giovanello, K.S., Smith, J.K., Shen, D., Gilmore, J.H., Lin, W., 2009. Evidence on the emergence of the brain's default network from 2-week-old to 2-year-old healthy pediatric subjects. *Proc. Natl. Acad. Sci. U. S. A.* 106, 6790–6795.
- Geng, X., Gouttard, S., Sharma, A., Gu, H., Styner, M., Lin, W., Gerig, G., Gilmore, J.H., 2012. Quantitative tract-based white matter development from birth to age 2years. *Neuroimage* 61, 542–557. doi:10.1016/j.neuroimage.2012.03.057
- Gilbert, S.F., 2000. *Developmental Biology*, 6th ed. Sinauer Associates, Sunderland.
- Glasser, M.F., Smith, S.M., Marcus, D.S., Andersson, J.L.R., Auerbach, E.J., Behrens, T.E.J.,

- Coalson, T.S., Harms, M.P., Jenkinson, M., Moeller, S., Robinson, E.C., Sotiropoulos, S.N., Xu, J., Yacoub, E., Ugurbil, K., Van Essen, D.C., 2016. The Human Connectome Project's neuroimaging approach. *Nat. Neurosci.* 19, 1175–87. doi:10.1038/nn.4361
- Goldman-Rakic, P.S., 1987. Development of cortical circuitry and cognitive function. *Child Dev.* 58, 601–622. doi:10.2307/1130201
- Grewen, K., 2015. Functional connectivity disruption in neonates with prenatal marijuana exposure 9, 1–14. doi:10.3389/fnhum.2015.00601
- Hagmann, P., Grant, P.E., Fair, D. a., 2012. MR connectomics: a conceptual framework for studying the developing brain. *Front. Syst. Neurosci.* 6, 1–17. doi:10.3389/fnsys.2012.00043
- Hagmann, P., Sporns, O., Madan, N., Cammoun, L., Pienaar, R., Wedeen, V.J., Meuli, R., Thiran, J.-P., Grant, P.E., 2010. White matter maturation reshapes structural connectivity in the late developing human brain. *Proc. Natl. Acad. Sci. U. S. A.* 107, 19067–72. doi:10.1073/pnas.1009073107
- Heep, A., Scheef, L., Jankowski, J., Born, M., Zimmermann, N., Sival, D., Bos, A., Gieseke, J., Bartmann, P., Schild, H., Boecker, H., 2009. Functional magnetic resonance imaging of the sensorimotor system in preterm infants. *Pediatrics* 123, 294–300. doi:10.1542/peds.2007-3475
- Hua, J.Y., Smith, S.J., 2004. Neural activity and the dynamics of central nervous system development. *Nat Neurosci* 7, 327–332. doi:10.1038/nn1218
- Huang, H., Shu, N., Mishra, V., Jeon, T., Chalak, L., Wang, Z.J., Rollins, N., Gong, G., Cheng, H., Peng, Y., Dong, Q., He, Y., 2013. Development of Human Brain Structural Networks Through Infancy and Childhood. *Cereb. Cortex* bht335. doi:10.1093/cercor/bht335
- Huang, H., Xue, R., Zhang, J., Ren, T., Richards, L.J., Yarowsky, P., Miller, M.I., Mori, S.,

2009. Anatomical Characterization of Human Fetal Brain Development with Diffusion Tensor Magnetic Resonance Imaging. *J. Neurosci.* 29, 4263–4273.  
doi:10.1523/JNEUROSCI.2769-08.2009
- Huang, H., Zhang, J., Wakana, S., Zhang, W., Ren, T., Richards, L.J., Yarowsky, P., Donohue, P., Graham, E., van Zijl, P.C.M., Mori, S., 2006. White and gray matter development in human fetal, newborn and pediatric brains. *Neuroimage* 33, 27–38.  
doi:10.1016/j.neuroimage.2006.06.009
- Huppi, P.S., Maier, S.E., Peled, S., Zientara, G.P., Barnes, P.D., Jolesz, F.A., Volpe, J.J., 1998. Microstructural Development of Human Newborn Cerebral White Matter Assessed in Vivo by Diffusion Tensor Magnetic Resonance Imaging. *Pediatr Res* 44, 584–590.
- Huttenlocher, P.R., Courten de, C., 1987. The development of synapses in striate cortex of man. *Hum. Neurobiol.* 6, 1–9.
- Huttenlocher, P.R., Dabholkar, A.S., 1997. Regional differences in synaptogenesis in human cerebral cortex. *J. Comp. Neurol.* 387, 167–178. doi:10.1002/(SICI)1096-9861(19971020)387:2<167::AID-CNE1>3.0.CO;2-Z
- Innocenti, G.M., Price, D.J., 2005. Exuberance in the development of cortical networks. *Nat. Rev. Neurosci.* 6, 955–965. doi:10.1038/nrn1790
- Jha, S.C., Meltzer-Brody, S., Steiner, R.J., Cornea, E., Woolson, S., Ahn, M., Verde, A.R., Hamer, R.M., Zhu, H., Styner, M., Gilmore, J.H., Knickmeyer, R.C., 2016. Antenatal depression, treatment with selective serotonin reuptake inhibitors, and neonatal brain structure: A propensity-matched cohort study. *Psychiatry Res. Neuroimaging* 253, 43–53. doi:10.1016/j.psychresns.2016.05.004
- Johnson, S., Hennessy, E., Smith, R., Trikić, R., Wolke, D., Marlow, N., 2009. Academic attainment and special educational needs in extremely preterm children at 11 years of

age: the EPICure study. *Arch. Dis. Child. Fetal Neonatal Ed.* 94, F283–F289.

doi:10.1136/adc.2008.152793

Johnson, S., Hollis, C., Kochhar, P., Hennessy, E., Wolke, D., Marlow, N., 2010. Psychiatric disorders in extremely preterm children: longitudinal finding at age 11 years in the EPICure study. *J. Am. Acad. Child Adolesc. Psychiatry* 49, 453–463.e1.

doi:10.1016/j.jaac.2010.02.002

Kapellou, O., Counsell, S.J., Kennea, N., Dyet, L., Saeed, N., Stark, J., Maalouf, E., Duggan, P., Ajayi-Obe, M., Hajnal, J., Allsop, J.M., Boardman, J., Rutherford, M.A., Cowan, F., Edwards, A.D., 2006. Abnormal cortical development after premature birth shown by altered allometric scaling of brain growth. *PLoS Med.* 3, 1382–1390.

doi:10.1371/journal.pmed.0030265

Keunen, K., Kersbergen, K.J., Groenendaal, F., Isgum, I., de Vries, L.S., Benders, M.J.N.L., 2012. Brain tissue volumes in preterm infants: prematurity, perinatal risk factors and neurodevelopmental outcome: A systematic review. *J. Matern. Neonatal Med.* 25, 89–100. doi:10.3109/14767058.2012.664343

Kinney, H.C., Brody, B. a, Kloman, a S., Gilles, F.H., 1988. Sequence of central nervous system myelination in human infancy: II. An autopsy study of myelination. *J. Neuropathol. Exp. Neurol.* 46, 283–301. doi:10.1097/00005072-198705000-00005

doi:10.1097/00005072-198705000-00005

Konishi, Y., Taga, G., Yamada, H., Hirasawa, K., 2002. Functional brain imaging using fMRI and optical topography in infancy. *Sleep Med.* 3 Suppl 2, S41–S43. doi:10.1016/S1389-9457(02)00163-6

Koolen, N., Dereymaeker, A., Ra, O., Jansen, K., Vervisch, J., Matic, V., Naulaers, G., Vos, M.D.E., Huffel, S.V.A.N., Vanhatalo, S., 2016. Early development of synchrony in cortical activations. *322*, 298–307. doi:10.1016/j.neuroscience.2016.02.017

Kostovic, I., 2002. Laminar Organization of the Human Fetal Cerebrum Revealed by

Histochemical Markers and Magnetic Resonance Imaging. *Cereb. Cortex* 12, 536–544.

doi:10.1093/cercor/12.5.536

Kostovic, I., Jovanov-Milocevic, N., Rados, M., Sedmak, G., Benjak, V., Kostovic-Srzentic, M., Vasung, L., Culjat, M., Rados, M., Huppi, P., Judas, M., 2014. Perinatal and early postnatal reorganization of the subplate and related cellular compartments in the human cerebral wall as revealed by histological and MRI approaches. *Brain Struct. Funct.* 219, 231–253. doi:10.1007/s00429-012-0496-0

Kostovic, I., Jovanov-Milosevic, N., 2006. The development of cerebral connections during the first 20-45 weeks' gestation. *Semin. Fetal Neonatal Med.* 11, 415–422.

doi:10.1016/j.siny.2006.07.001

Kostovic, I., Rakic, P., 1980. Cytology and time of origin of interstitial neurons in the white matter in infant and adult human and monkey telencephalon. *J. Neurocytol.* 9, 219–242.

doi:10.1007/BF01205159

Kostovic, I., Vasung, L., 2009. Insights From In Vitro Fetal Magnetic Resonance Imaging of Cerebral Development. *Semin. Perinatol.* 33, 220–233.

doi:10.1053/j.semperi.2009.04.003

Krishnan, M.L., Wang, Z., Silver, M., Boardman, J.P., Ball, G., Counsell, S.J., Walley, A.J., Montana, G., Edwards, A.D., 2016. Possible relationship between common genetic variation and white matter development in a pilot study of preterm infants. *Brain Behav.* 434, 1–14. doi:10.1002/brb3.434

Kwon, S.H., Scheinost, D., Lacadie, C., Sze, G., Schneider, K.C., Dai, F., Constable, R.T., Ment, L.R., 2015. Adaptive mechanisms of developing brain: Cerebral lateralization in the prematurely-born. *Neuroimage* 108, 144–150. doi:10.1016/j.neuroimage.2014.12.032

LaMantia, A.S., Rakic, P., 1990. Axon overproduction and elimination in the corpus callosum of the developing rhesus monkey. *J. Neurosci.* 10, 2156–2175.

doi:10.1002/cne.903400304

- Laumann, T.O., Snyder, A.Z., Mitra, A., Gordon, E.M., Gratton, C., Adeyemo, B., Gilmore, A.W., Nelson, S.M., Berg, J.J., Greene, D.J., McCarthy, J.E., Tagliazucchi, E., Laufs, H., Schlaggar, B.L., Dosenbach, N.U.F., Petersen, S.E., 2016. On the Stability of BOLD fMRI Correlations. *Cereb. Cortex* 1–14. doi:10.1093/cercor/bhw265
- Lin, W., Zhu, Q., Gao, W., Chen, Y., Toh, C., Gerig, G., Smith, J.K., Biswal, B., Gilmore, J.H., 2008. Functional Connectivity MR Imaging Reveals Cortical Functional Connectivity in the Developing Brain 1883–1889. doi:10.3174/ajnr.A1256
- Lodygensky, G.A., Vasung, L., Sizonenko, S. V, Hüppi, P.S., 2010. Neuroimaging of cortical development and brain connectivity in human newborns and animal models. *J. Anat.* 217, 418–428. doi:10.1111/j.1469-7580.2010.01280.x
- Lowe, M.J., Sakaie, K.E., Beall, E.B., Calhoun, V.D., Bridwell, D.A., Rubinov, M., Rao, S.M., 2016. Modern Methods for Interrogating the Human Connectome. *J. Int. Neuropsychol. Soc.* 22, 105–119. doi:10.1017/S1355617716000060
- Maas, L.C., Mukherjee, P., Carballido-Gamio, J., Veeraraghavan, S., Miller, S.P., Partridge, S.C., Henry, R.G., Barkovich, A.J., Vigneron, D.B., 2004. Early laminar organization of the human cerebrum demonstrated with diffusion tensor imaging in extremely premature infants. *Neuroimage* 22, 1134–1140. doi:10.1016/j.neuroimage.2004.02.035
- Moeskops, P., Benders, M.J.N.L., Kersbergen, K.J., Groenendaal, F., De Vries, L.S., Viergever, M.A., I?gum, I., 2015. Development of cortical morphology evaluated with longitudinal MR brain images of preterm infants. *PLoS One* 10, 1–22. doi:10.1371/journal.pone.0131552
- Monson, B.B., Anderson, P.J., Matthews, L.G., Neil, J.J., Kapur, K., Cheong, J.L.Y., Doyle, L.W., Thompson, D.K., Inder, T.E., 2016. Examination of the Pattern of Growth of Cerebral Tissue Volumes From Hospital Discharge to Early Childhood in Very Preterm

- Infants. *JAMA Pediatr.* 8, 110–124. doi:10.1001/JAMAPEDIATRICS.2016.0781
- Morita, T., Kochiyama, T., Yamada, H., Konishi, Y., Yonekura, Y., Matsumura, M., Sadato, N., 2000. Difference in the metabolic response to photic stimulation of the lateral geniculate nucleus and the primary visual cortex of infants: A fMRI study. *Neurosci. Res.* 38, 63–70. doi:10.1016/S0168-0102(00)00146-2
- Oishi, K., Mori, S., Donohue, P.K., Ernst, T., Anderson, L., Buchthal, S., Faria, A., Jiang, H., Li, X., Miller, M.I., Peter, C.M., Zijl, V., Chang, L., 2012. NIH Public Access 56, 8–20. doi:10.1016/j.neuroimage.2011.01.051.Multi-Contrast
- Omidvarnia, A., Fransson, P., Metsäranta, M., Vanhatalo, S., 2014. Functional bimodality in the brain networks of preterm and term human newborns. *Cereb. Cortex* 24, 2657–2668. doi:10.1093/cercor/bht120
- Omidvarnia, A., Metsäranta, M., Lano, A., Vanhatalo, S., 2015. NeuroImage Structural damage in early preterm brain changes the electric resting state networks ☆. *Neuroimage* 120, 266–273. doi:10.1016/j.neuroimage.2015.06.091
- Papile, L.A., Burstein, J., Burstein, R., Koffler, H., 1978. Incidence and evolution of subependymal and intraventricular hemorrhage: A study of infants with birth weights less than 1,500 gm. *J. Pediatr.* 92, 529–534. doi:10.1016/S0022-3476(78)80282-0
- Partridge, S.C., Mukherjee, P., Henry, R.G., Miller, S.P., Berman, J.I., Jin, H., Lu, Y., Glenn, O.A., Ferriero, D.M., Barkovich, A.J., Vigneron, D.B., 2004. Diffusion tensor imaging: Serial quantitation of white matter tract maturity in premature newborns. *Neuroimage* 22, 1302–1314. doi:10.1016/j.neuroimage.2004.02.038
- Power, J.D., Barnes, K.A., Snyder, A.Z., Schlaggar, B.L., Petersen, S.E., 2012. Spurious but systematic correlations in functional connectivity MRI networks arise from subject motion. *Neuroimage* 59, 2142–2154. doi:10.1016/j.neuroimage.2011.10.018
- Power, J.D., Fair, D. a., Schlaggar, B.L., Petersen, S.E., 2010. The Development of Human

- Functional Brain Networks. *Neuron* 67, 735–748. doi:10.1016/j.neuron.2010.08.017
- Power, J.D., Schlaggar, B.L., Petersen, S.E., 2015. Recent progress and outstanding issues in motion correction in resting state fMRI. *Neuroimage* 105, 536–551. doi:10.1016/j.neuroimage.2014.10.044
- Qiu, A., Anh, T.T., Li, Y., Chen, H., Rifkin-Graboi, A., Broekman, B.F.P., Kwek, K., Saw, S.-M., Chong, Y.-S., Gluckman, P.D., Fortier, M. V, Meaney, M.J., 2015. Prenatal maternal depression alters amygdala functional connectivity in 6-month-old infants. *Transl. Psychiatry* 5, e508. doi:10.1038/tp.2015.3
- Raichle, M.E., MacLeod, A.M., Snyder, A.Z., Powers, W.J., Gusnard, D.A., Shulman, G.L., 2001. A default mode of brain function. *Proc. Natl. Acad. Sci. U. S. A.* 98, 676–82. doi:10.1073/pnas.98.2.676
- Rakic, P., Sidman, R., 1970. Histogenesis of cortical layers in human cerebellum, particularly the lamina dissecans. *J. Comput. Neurol.* 139, 473–500.
- Rathbone, R., Counsell, S.J., Kapellou, O., Dyet, L., Kennea, N., Hajnal, J., Allsop, J.M., Cowan, F., Edwards, a D., 2011. Perinatal cortical growth and childhood neurocognitive abilities. *Neurology* 77, 1510–7. doi:10.1212/WNL.0b013e318233b215
- Ratnarajah, N., Rifkin-graboi, A., Fortier, M. V, Seng, Y., Kwek, K., Saw, S., Godfrey, K.M., Gluckman, P.D., Meaney, M.J., Qiu, A., 2013. NeuroImage Structural connectivity asymmetry in the neonatal brain. *Neuroimage* 75, 195–202. doi:10.1016/j.neuroimage.2013.02.052
- Ross, E.J., Graham, D.L., Money, K.M., Stanwood, G.D., 2015. Developmental consequences of fetal exposure to drugs: what we know and what we still must learn. *Neuropsychopharmacology* 40, 61–87. doi:10.1038/npp.2014.147
- Rubinov, M., Sporns, O., 2010. Complex network measures of brain connectivity: Uses and interpretations. *Neuroimage* 52, 1059–1069. doi:10.1016/j.neuroimage.2009.10.003

- Sadeghi, N., Prastawa, M., Fletcher, P.T., Wolff, J., Gilmore, J.H., Gerig, G., 2013. Regional characterization of longitudinal DT-MRI to study white matter maturation of the early developing brain. *Neuroimage* 68, 236–247. doi:10.1016/j.neuroimage.2012.11.040
- Salzwedel, A.P., Grewen, K.M., Goldman, B.D., Gao, W., 2016. Neurotoxicology and Teratology Thalamocortical functional connectivity and behavioral disruptions in neonates with prenatal cocaine exposure. *Neurotoxicol. Teratol.* 56, 16–25. doi:10.1016/j.ntt.2016.05.009
- Salzwedel, A.P., Grewen, X.K.M., Vachet, X.C., Gerig, G., Lin, W., Gao, X.W., 2015. Prenatal Drug Exposure Affects Neonatal Brain Functional Connectivity 35, 5860–5869. doi:10.1523/JNEUROSCI.4333-14.2015
- Satterthwaite, T.D., Elliott, M.A., Gerraty, R.T., Ruparel, K., Loughhead, J., Calkins, M.E., Eickhoff, S.B., Hakonarson, H., Gur, R.C., Gur, R.E., Wolf, D.H., 2013. An improved framework for confound regression and filtering for control of motion artifact in the preprocessing of resting-state functional connectivity data. *Neuroimage* 64, 240–256. doi:10.1016/j.neuroimage.2012.08.052
- Scheinost, D., Kwon, S.H., Shen, X., Lacadie, C., Schneider, K.C., Dai, F., Ment, L.R., Constable, R.T., 2015. Preterm birth alters neonatal, functional rich club organization. *Brain Struct. Funct.* doi:10.1007/s00429-015-1096-6
- Scholtens, L.H., Schmidt, R., de Reus, M. a, van den Heuvel, M.P., 2014. Linking macroscale graph analytical organization to microscale neuroarchitectonics in the macaque connectome. *J. Neurosci.* 34, 12192–205. doi:10.1523/JNEUROSCI.0752-14.2014
- Schöpf, V., Kasprian, G., Brugger, P.C., Prayer, D., 2012. Watching the fetal brain at “rest.” *Int. J. Dev. Neurosci.* 30, 11–17. doi:10.1016/j.ijdevneu.2011.10.006
- Seshamani, S., Cheng, X., Fogtman, M., Thomason, M.E., Studholme, C., 2014. A Method for handling intensity inhomogenities in fMRI sequences of moving anatomy of the

early developing brain. *Med. Image Anal.* 18, 285–300.

doi:10.1016/j.media.2013.10.011

Shankle, W.R., Rafil, M.S., Landing, B.H., Fallon, J.H., 1999. Approximate Doubling of Numbers of Neurons in Postnatal Human Cerebral Cortex and in 35 Specific Cytoarchitectural Areas from Birth to 72 Months. *Pediatr. Dev. Pathol.* 2, 244–259.

Shi, F., Yap, P.T., Gao, W., Lin, W., Gilmore, J.H., Shen, D., 2012. Altered structural connectivity in neonates at genetic risk for schizophrenia: A combined study using morphological and white matter networks. *Neuroimage* 62, 1622–1633.

doi:10.1016/j.neuroimage.2012.05.026

Shimony, J.S., Smyser, C.D., Wideman, G., Alexopoulos, D., Hill, J., Harwell, J., Dierker, D., Van Essen, D.C., Inder, T.E., Neil, J.J., 2016. Comparison of cortical folding measures for evaluation of developing human brain. *Neuroimage* 125, 780–790.

doi:10.1016/j.neuroimage.2015.11.001

Smith, S.M., Fox, P.T., Miller, K.L., Glahn, D.C., Fox, P.M., Mackay, C.E., Filippini, N., Watkins, K.E., Toro, R., Laird, A.R., Beckmann, C.F., 2009. Correspondence of the brain's functional architecture during activation and rest. *Proc. Natl. Acad. Sci. U. S. A.* 106, 13040–5. doi:10.1073/pnas.0905267106

Smyser, C., Grabowski, T.J., Frank, R.J., Haller, J.W., Bolinger, L., 2001. Real-time multiple linear regression for fMRI supported by time-aware acquisition and processing. *Magn. Reson. Med.* 45, 289–298. doi:10.1002/1522-2594(200102)45:2<289::AID-MRM1038>3.0.CO;2-U

Smyser, C.D., Inder, T.E., Shimony, J.S., Hill, J.E., Degnan, A.J., Snyder, A.Z., Neil, J.J., 2010. Longitudinal analysis of neural network development in preterm infants. *Cereb. Cortex* 20, 2852–2862. doi:10.1093/cercor/bhq035

Smyser, C.D., Snyder, A.Z., Shimony, J.S., Blazey, T.M., Inder, T.E., Neil, J.J., 2013. Effects

of White Matter Injury on Resting State fMRI Measures in Prematurely Born Infants 8.

doi:10.1371/journal.pone.0068098

Smyser, C.D., Snyder, A.Z., Shimony, J.S., Mitra, A., Inder, T.E., Neil, J.J., 2016. Resting-

State Network Complexity and Magnitude Are Reduced in Prematurely Born Infants

322–333. doi:10.1093/cercor/bhu251

Stiles, J., Jernigan, T.L., 2010. The basics of brain development. *Neuropsychol. Rev.* 20, 327–

348. doi:10.1007/s11065-010-9148-4

Striedter, G.F., Srinivasan, S., Monuki, E.S., 2014. Cortical Folding: When, Where, How, and

Why? *Annu. Rev. Neurosci.* 38, 150421150146009. doi:10.1146/annurev-neuro-071714-

034128

Takahashi, E., Folkerth, R.D., Galaburda, A.M., Grant, P.E., 2012. Emerging cerebral

connectivity in the human fetal Brain: An MR tractography study. *Cereb. Cortex* 22,

455–464. doi:10.1093/cercor/bhr126

Thomason, M.E., Brown, J.A., Dassanayake, M.T., Shastri, R., Marusak, H.A., Hernandez-

Andrade, E., Yeo, L., Mody, S., Berman, S., Hassan, S.S., Romero, R., 2014. Intrinsic

functional brain architecture derived from graph theoretical analysis in the human fetus.

*PLoS One.* doi:10.1371/journal.pone.0094423

Thomason, M.E., Grove, L.E., Lozon, T.A., Vila, A.M., Ye, Y., Nye, M.J., Manning, J.H.,

Pappas, A., Hernandez-Andrade, E., Yeo, L., Mody, S., Berman, S., Hassan, S.S.,

Romero, R., 2015. Age-related increases in long-range connectivity in fetal functional

neural connectivity networks in utero. *Dev. Cogn. Neurosci.* 11, 96–104.

doi:10.1016/j.dcn.2014.09.001

Thomason, M.E., Thomason, M.E., Dassanayake, M.T., Shen, S., Katkuri, Y., Hassan, S.S.,

Studholme, C., Jeong, J., Romero, R., 2013. Cross-Hemispheric Functional Connectivity

in the Human Fetal Brain. *Sci. Transl. Med.* 24, 173ra24-173ra24.

doi:10.1126/scitranslmed.3004978

- Tokariev, A., Videman, M., Palva, J.M., Vanhatalo, S., 2015. Functional Brain Connectivity Develops Rapidly Around Term Age and Changes Between Vigilance States in the Human Newborn 1–11. doi:10.1093/cercor/bhv219
- Tolonen, M., Palva, J.M., Andersson, S., Vanhatalo, S., 2007. Development of the spontaneous activity transients and ongoing cortical activity in human preterm babies. *Neuroscience* 145, 997–1006. doi:10.1016/j.neuroscience.2006.12.070
- Toulmin, H., Beckmann, C.F., O’Muircheartaigh, J., Ball, G., Nongena, P., Makropoulos, A., Ederies, A., Counsell, S.J., Kennea, N., Arichi, T., Tusor, N., Rutherford, M.A., Azzopardi, D., Gonzalez-Cinca, N., Hajnal, J. V, Edwards, A.D., 2015. Specialization and integration of functional thalamocortical connectivity in the human infant. *Proc. Natl. Acad. Sci.* 112, 6485–6490. doi:10.1073/pnas.1422638112
- Tymofiyeva, O., Hess, C.P., Ziv, E., Lee, P.N., Glass, H.C., Ferriero, D.M., Barkovich, A.J., Xu, D., 2013. A DTI-Based Template-Free Cortical Connectome Study of Brain Maturation. *PLoS One* 8, 1–10. doi:10.1371/journal.pone.0063310
- Tymofiyeva, O., Hess, C.P., Ziv, E., Tian, N., Bonifacio, S.L., McQuillen, P.S., Ferriero, D.M., Barkovich, A.J., Xu, D., 2012. Towards the “baby connectome”: Mapping the structural connectivity of the newborn brain. *PLoS One* 7. doi:10.1371/journal.pone.0031029
- Urban, S., Van Hanswijck De Jonge, L., Barisnikov, K., Pizzo, R., Monnier, M., Lazeyras, F., Borradori Tolsa, C., Hüppi, P.S., 2015. Gestational age and gender influence on executive control and its related neural structures in preterm-born children at 6 years of age. *Child Neuropsychol.* 7049, 1–20. doi:10.1080/09297049.2015.1099619
- van den Heuvel, M.P., Kersbergen, K.J., de Reus, M.A., Keunen, K., Kahn, R.S., Groenendaal, F., de Vries, L.S., Benders, M.J.N.L., 2014. The Neonatal Connectome

- During Preterm Brain Development. *Cereb. Cortex* 1–14. doi:10.1093/cercor/bhu095
- van Dijk, K.R.A., Sabuncu, M.R., Buckner, R.L., 2012. The influence of head motion on intrinsic functional connectivity MRI. *Neuroimage* 59, 431–438. doi:10.1016/j.neuroimage.2011.07.044
- Vanhatalo, S., Kaila, K., 2006. Development of neonatal EEG activity: From phenomenology to physiology. *Semin. Fetal Neonatal Med.* 11, 471–478. doi:10.1016/j.siny.2006.07.008
- Vasung, L., Huang, H., Jovanov-Milosevic, N., Pletikos, M., Mori, S., Kostovic, I., 2010. Development of axonal pathways in the human fetal fronto-limbic brain: Histochemical characterization and diffusion tensor imaging. *J. Anat.* 217, 400–417. doi:10.1111/j.1469-7580.2010.01260.x
- Videman, M., Tokariev, A., Saikkonen, H., Stjerna, S., Heiskala, H., Mantere, O., Vanhatalo, S., 2016. Newborn Brain Function Is Affected by Fetal Exposure to Maternal Serotonin Reuptake Inhibitors 1–9. doi:10.1093/cercor/bhw153
- Volpe, J.J., 2009. Brain injury in premature infants: a complex amalgam of destructive and developmental disturbances. *Lancet Neurol.* 8, 110–124. doi:10.1016/S1474-4422(08)70294-1
- Webb, S.J., Monk, C.S., Charles, a, 2001. Developmental neuropsychology mechanisms of postnatal neurobiological development: implications for human development. *Dev. Neuropsychol.* 19, 147–171. doi:10.1207/S15326942DN1902
- Welker, K.M., Patton, A., 2012. Assessment of normal myelination with magnetic resonance imaging. *Semin. Neurol.* 32, 15–28. doi:10.1055/s-0032-1306382
- WHO Multicentre Growth Reference Study Group, 2006. WHO Motor Development Study: windows of achievement for six gross motor development milestones. *Acta Paediatr. Int. J. Paediatr.* 450, 86–95.
- Yap, P.T., Fan, Y., Chen, Y., Gilmore, J.H., Lin, W., Shen, D., 2011. Development trends of

white matter connectivity in the first years of life. PLoS One 6.

doi:10.1371/journal.pone.0024678

Zuo, X.N., Xing, X.X., 2014. Test-retest reliabilities of resting-state FMRI measurements in human brain functional connectomics: A systems neuroscience perspective. *Neurosci. Biobehav. Rev.* 45, 100–118. doi:10.1016/j.neubiorev.2014.05.009

**Box 1** Neural network formation in the developing human brain can be studied at different levels. On the microscale, pioneering work has been done to delineate neural circuit establishment in the cortex, subplate, thalamus and cerebellum (Innocenti and Price, 2005; Kostovic et al., 2014; Rakic and Sidman, 1970). On a macroscopic level, an increasing literature converges upon the principles of whole-brain network development: the connectome. Structural brain wiring can be investigated using diffusion weighted imaging techniques. Connections reflect white matter pathways consisting of axonal fiber bundles and supporting glia cells (astrocytes, oligodendrocytes, microglia). Similarly, brain regions are considered *functionally* connected when their activation signals (e.g. blood oxygen-level dependent 'BOLD' signal or electroencephalography trace) follow a similar pattern over time and are temporally correlated. When these structural and functional connections are charted for all brain regions, such reconstructions result in a connectome map. Next, the topological features of the brain's connectivity matrix (connectome map) can be examined (see (Rubinov and Sporns, 2010) for a comprehensive review of network measures). Here we will discuss a number of key attributes of the human connectome that have been studied in the early developing brain. Complementary illustrations are provided in the toy network below.

Similar to the adult connectome, the neonatal brain has repeatedly been found to display short *characteristic path length*, which is computed as the average number of edges that need to be

traversed to travel between nodes of the network (panel A). Concomitantly, newborn infants exhibit a high level of *clustering*. Clustering reflects the tendency of the neighbors of a node to form connections, resulting in triangles of interconnected nodes (panel B). Together, short characteristic path length and high clustering compose '*small worldness*', a hallmark of human brain organization that is already present during the earliest phases of brain development, as soon as paramount connections have come into place. *Modularity* (panel C) measures the number of subnetworks ('*modules*') that the connectome encompasses. Functional modules identified during early development are spatially proximate, involving primary order brain regions. In the neonatal brain, clustering and modularity as metrics of segregation prevail, while levels of integration are relatively limited. Another important feature of the infant brain network is a *rich club* organization (panel D), meaning that its highest degree nodes (i.e. *hub* nodes (panel E)) are more strongly connected to each other than one would expect based on chance alone, in accordance with adult brain organization. The rich club coefficient is computed based on comparison against the organization of random networks. The overall spatial layout of *structural* hub nodes in the neonatal connectome shows substantial overlap with the adult human brain, while the configuration of *functional* hubs is still immature. Functional brain hubs are essentially confined to primary brain regions (e.g. sensorimotor and primary visual cortex). Hence, postnatal trajectories of functional brain wiring are more profound than maturational courses of structural brain network development. Structural refinements revolve around improvement of communication efficiency and connection strength, resulting in shorter characteristic path length, decreasing radial and axial diffusivity and increasing fractional anisotropy. During postnatal development, functional brain architecture transforms its spatial arrangement with brain hubs shifting from predominantly primary order brain regions to higher-order association areas.

**Figure 1 - Gantt chart of developmental processes and corresponding neuroimaging and electroencephalography findings from the embryonic phase until age one year.**

Schematic overview based on findings by (Alcauter et al., 2014; Bystron et al., 2008; Gao et al., 2011; Innocenti and Price, 2005; Kostovic et al., 2014; Kostovic and Rakic, 1980; Kostovic and Vasung, 2009; Shankle et al., 1999; Stiles and Jernigan, 2010; Thomason et al., 2013, 2015; Vanhatalo and Kaila, 2006; Vasung et al., 2010). Upper panel indicates developmental processes and lower panel portrays corresponding neuroimaging and electroencephalography findings. Intensity of color bars illustrates the course of developmental trajectories. Asterisks indicate that earlier prenatal imaging data are not available. Therefore, exact timing of emergence is as yet unclear. Axonal elimination (pinkish-red bar) is a predominantly postnatal process, yet axons in the subplate begin to diminish from 32-34 PCW. DWI = diffusion weighted imaging, EEG = electroencephalography, FA = fractional anisotropy, fMRI = resting state functional MRI, PCW = postconceptional weeks, SATs = spontaneous activity transients.

**Figure 2 - Graphic representation of developmental trajectories of major white matter pathways.** Panel A. Projection fibers have been traced from 8-10 postconceptional weeks (PCW) and include the corticospinal tract that expands from the internal capsule.

Thalamocortical projection fibers reach their destination in the developing cortex between 24-32 PCW. Panel B. Commissural fibers of the corpus callosum are detectable from 11-13 PCW and reach the cortex in the late second to early third trimester (26-32 PCW), closely following the developmental trajectory of thalamocortical projection fibers. Panel C. Association fibers appear at different stages. The initial formation of the inferior fronto-occipital peduncle and inferior longitudinal fasciculus occurs at around 17-19 PCW. Long-range association fibers do not undergo significant development until the third trimester of pregnancy (33-35 PCW),

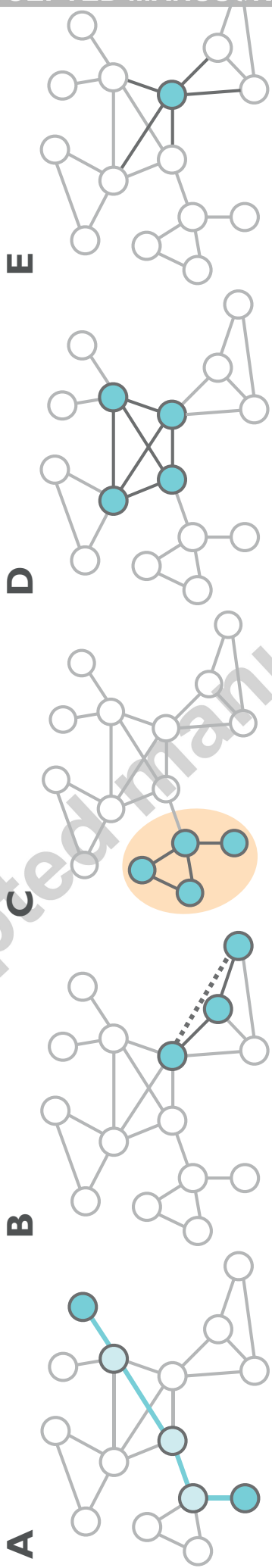
although the superior longitudinal fasciculus is not yet prominent at birth. Schematic overview based on findings by (Huang et al., 2009; Kostovic and Jovanov-Milosevic, 2006; Takahashi et al., 2012; Vasung et al., 2010).

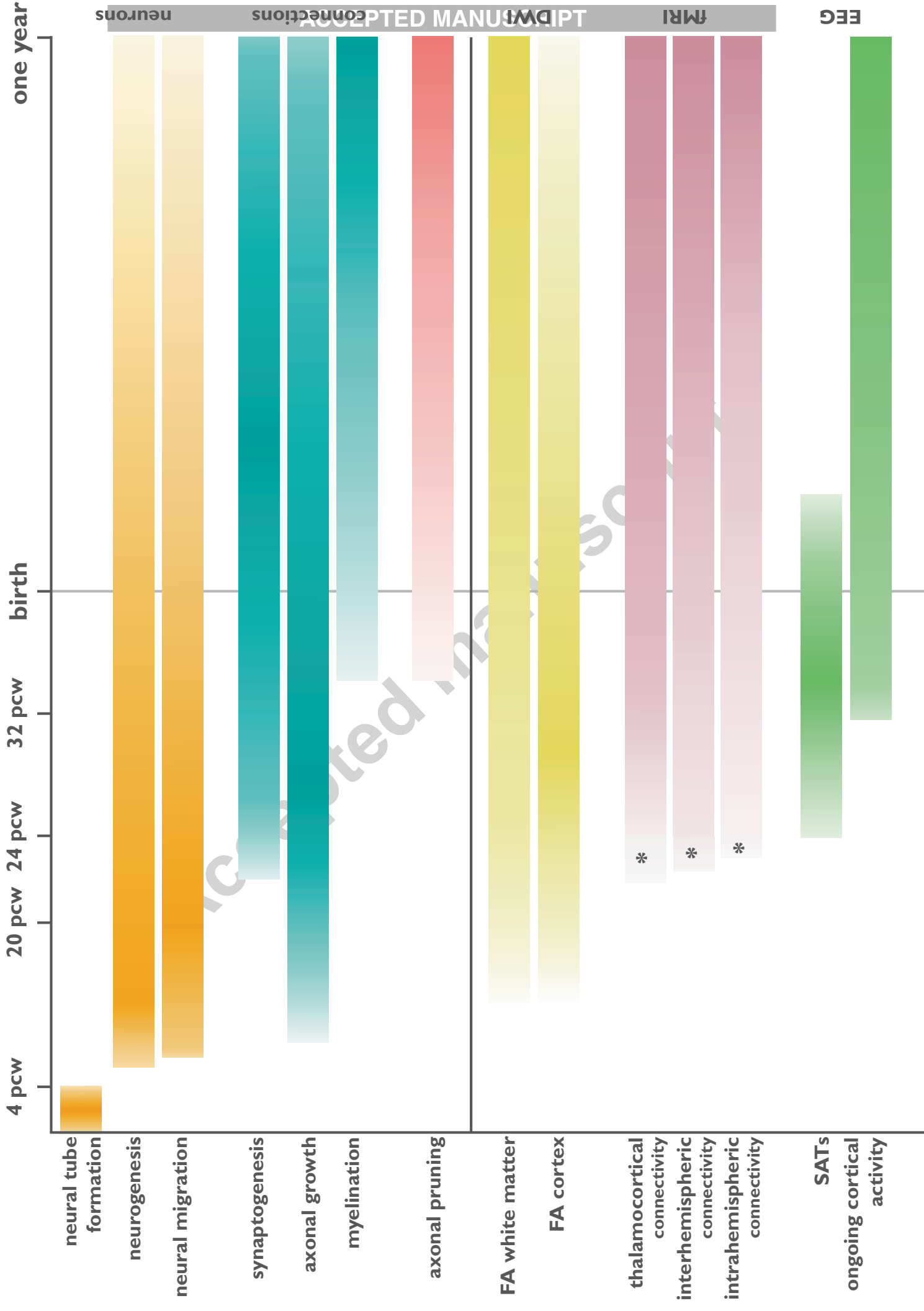
**Figure 3 - Resting state networks in the neonatal brain.** Resting state networks as detected in the neonatal brain employing probabilistic independent component analysis on resting-state functional MRI data. Color bar indicates Z-statistic of functional connectivity strength. Adapted from Doria et al. PNAS 2010 (Doria et al., 2010a), with permission.

**Figure 4 - Schematic illustration of default mode network development.** Development of the default mode network in the prenatal period (top row) and the first postnatal year (bottom row) as revealed by resting state fMRI studies. Illustration based on (Doria et al., 2010a; Gao et al., 2014a; Smyser et al., 2010; Thomason et al., 2015). Please note that preprocessing and region of interest (ROI) selection differed between studies (see section on Methodological considerations). The fetal imaging study by (Thomason et al., 2015) adopted the ROIs provided in (Smyser et al., 2010). (Doria et al., 2010a) also performed manual ROI placement and (Gao et al., 2014a) employed adult BrainMap data to define seed-regions (Smith et al., 2009). PCW = postconceptional weeks.

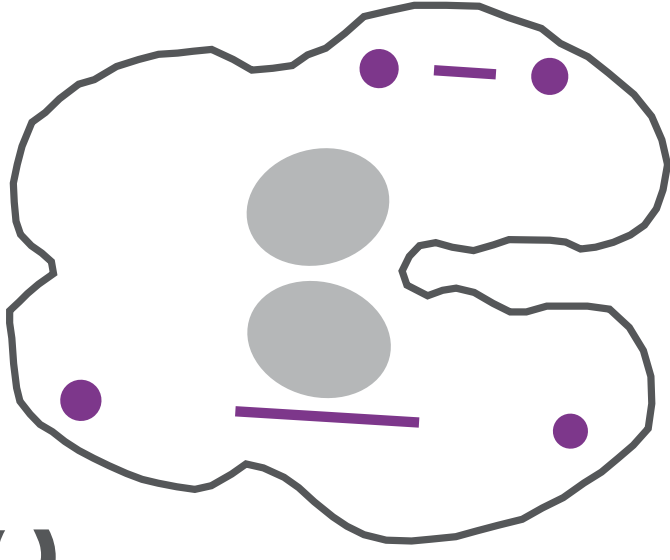
### Highlights

- Interhemispheric functional coupling has been noted in the fetal brain from 24 PCW
- The overall framework of mature brain wiring is established by the time of birth
- Development of functional architecture follows a primary-to-higher order sequence
- Prematurity disrupts long-range connectivity of primarily thalamocortical pathways
- Prenatal substance exposure affects receptor regions and amygdala-frontal circuits

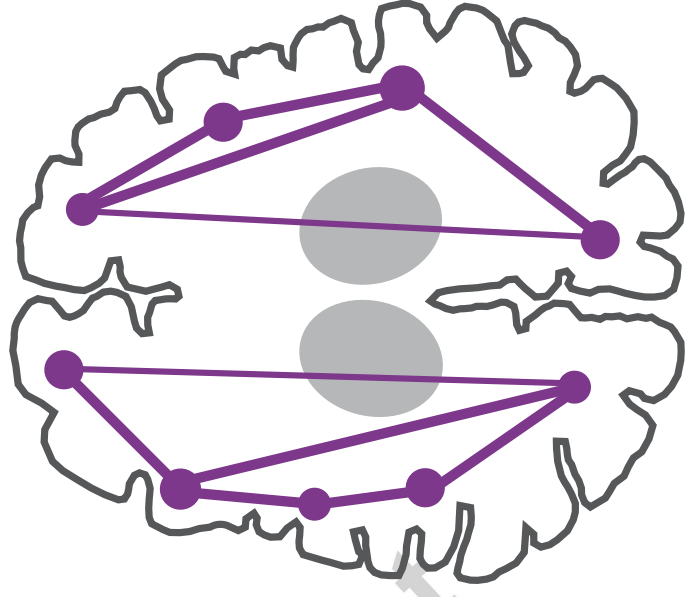




C

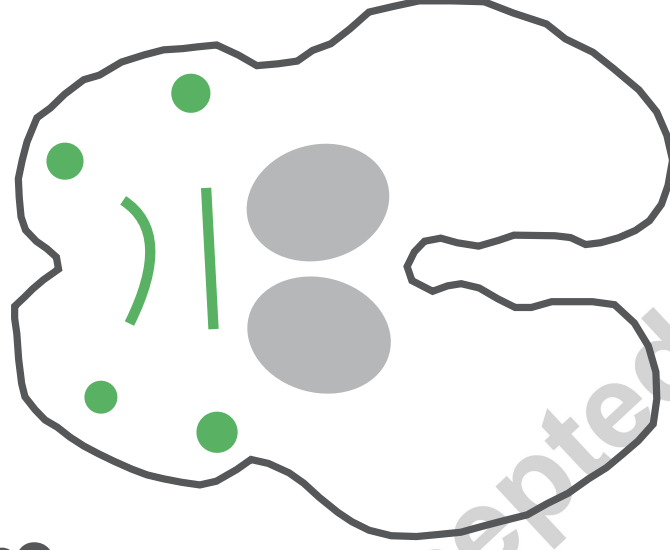


17-19 pcw

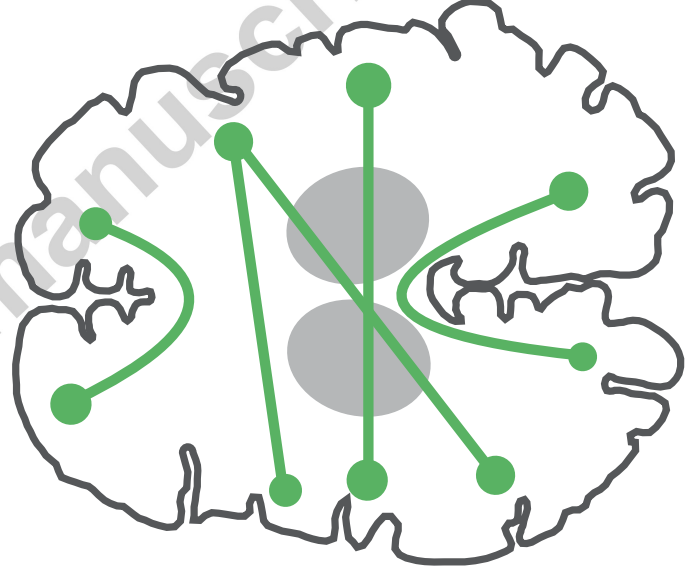


33-35 pcw

B

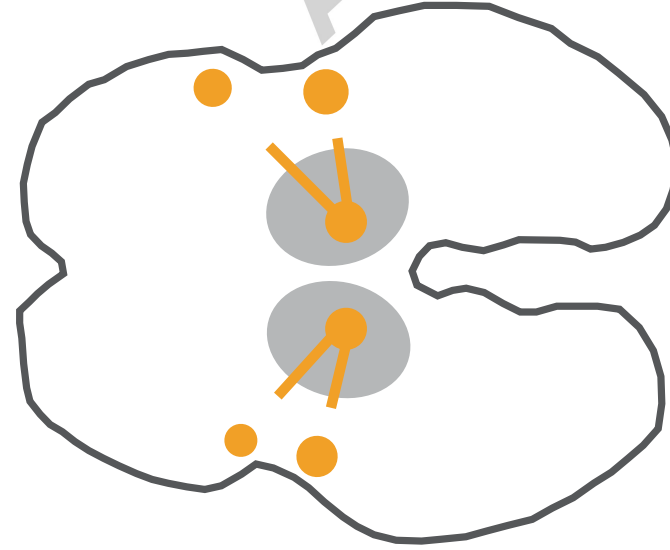

11-13 pcw

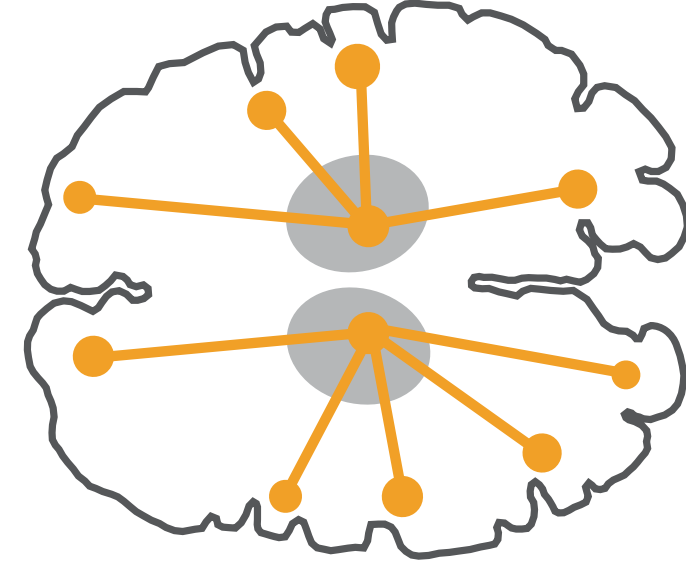


26-32 pcw

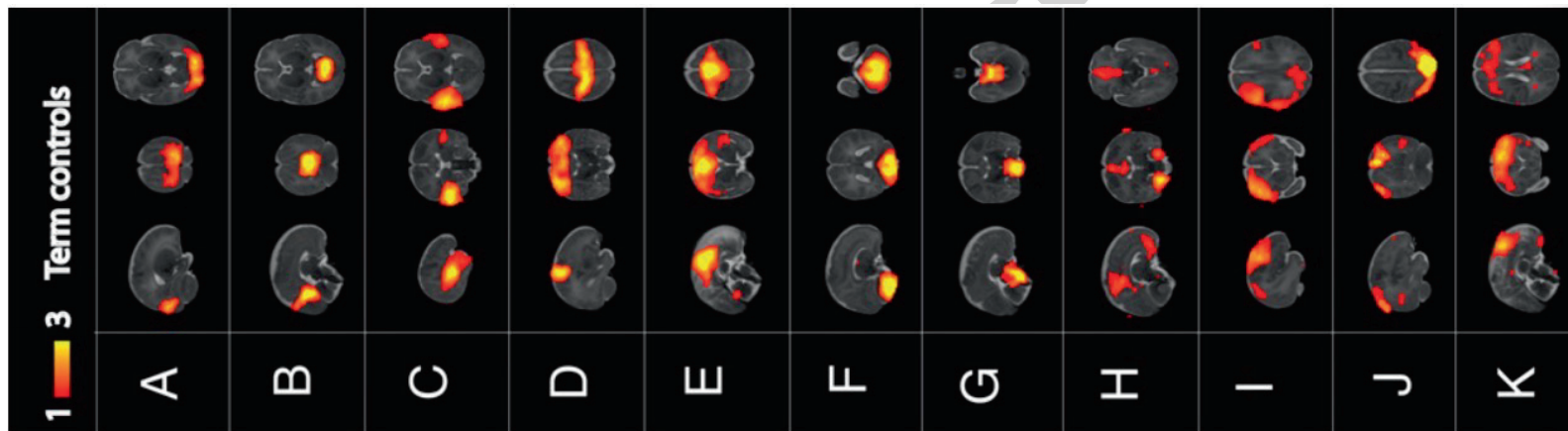
A

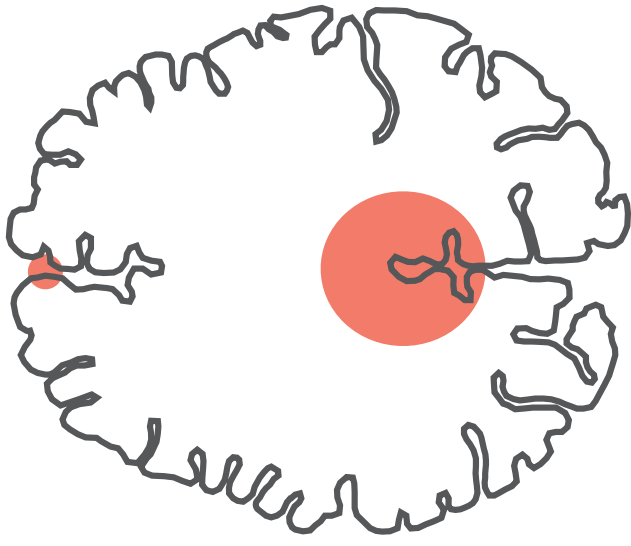


8-10 pcw

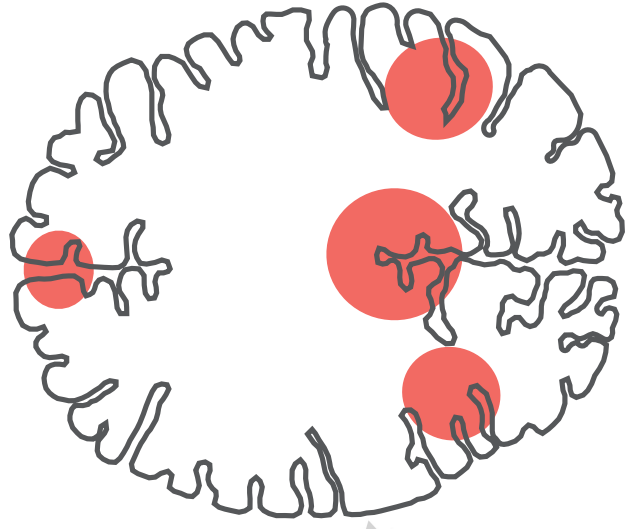


24-32 pcw

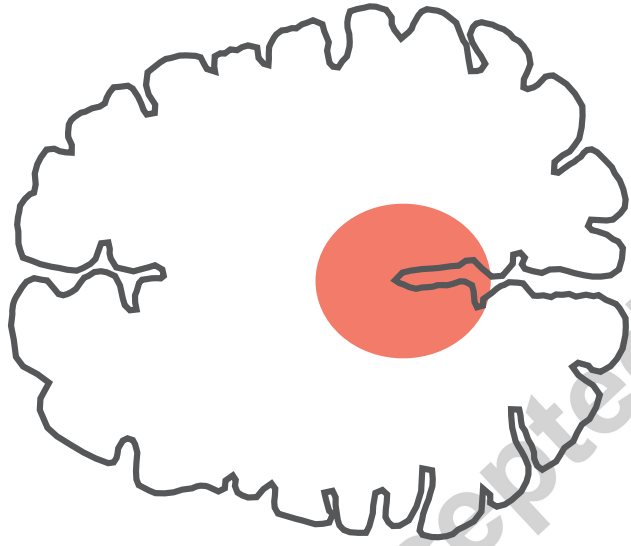




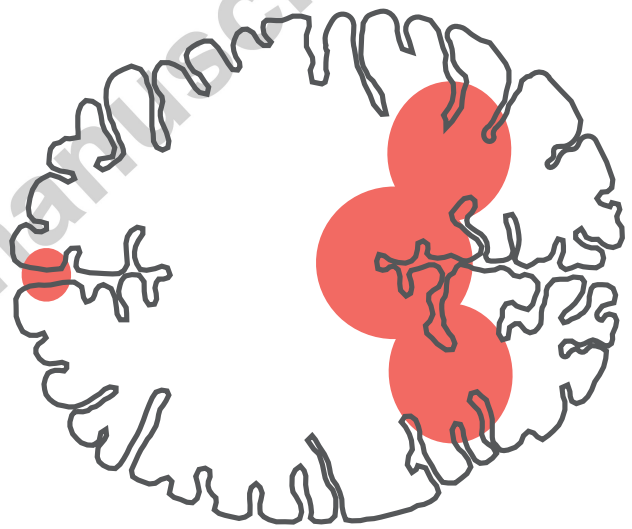
35-38 pcw



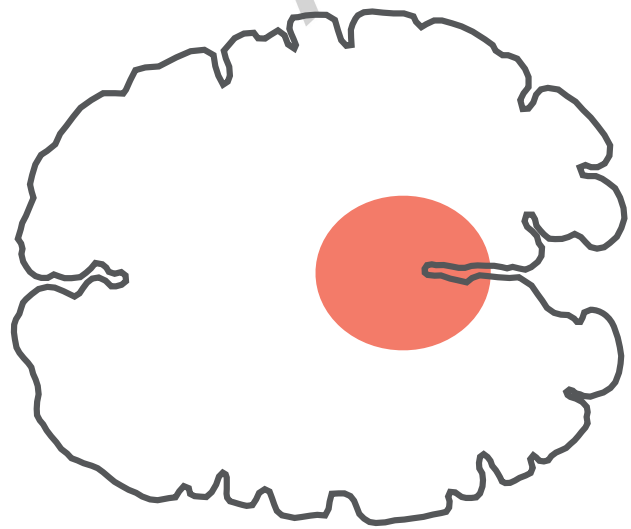
12 months



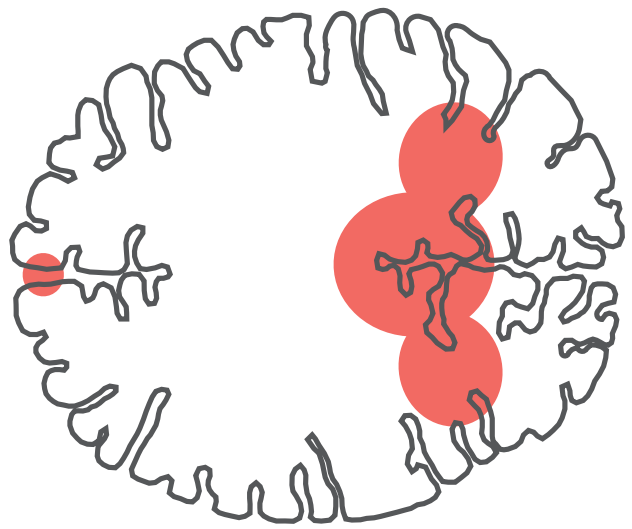
30-34 pcw



6 months



25-29 pcw



0-3 months