



## King's Research Portal

DOI:

[10.1016/j.hjc.2018.11.004](https://doi.org/10.1016/j.hjc.2018.11.004)

*Document Version*

Publisher's PDF, also known as Version of record

[Link to publication record in King's Research Portal](#)

*Citation for published version (APA):*

Theodoropoulos, K. C., Papachristidis, A., Fonseca, T., Reiken, J., & Monaghan, M. J. (2019). Understanding the anatomy of a perforated mitral valve: From 2D echocardiography to 3D printing. *Hellenic Journal of Cardiology*, 60(4), 264-265. <https://doi.org/10.1016/j.hjc.2018.11.004>

### **Citing this paper**

Please note that where the full-text provided on King's Research Portal is the Author Accepted Manuscript or Post-Print version this may differ from the final Published version. If citing, it is advised that you check and use the publisher's definitive version for pagination, volume/issue, and date of publication details. And where the final published version is provided on the Research Portal, if citing you are again advised to check the publisher's website for any subsequent corrections.

### **General rights**

Copyright and moral rights for the publications made accessible in the Research Portal are retained by the authors and/or other copyright owners and it is a condition of accessing publications that users recognize and abide by the legal requirements associated with these rights.

- Users may download and print one copy of any publication from the Research Portal for the purpose of private study or research.
- You may not further distribute the material or use it for any profit-making activity or commercial gain
- You may freely distribute the URL identifying the publication in the Research Portal

### **Take down policy**

If you believe that this document breaches copyright please contact [librarypure@kcl.ac.uk](mailto:librarypure@kcl.ac.uk) providing details, and we will remove access to the work immediately and investigate your claim.



## Letter to the Editor

## Understanding the anatomy of a perforated mitral valve: From 2D echocardiography to 3D printing

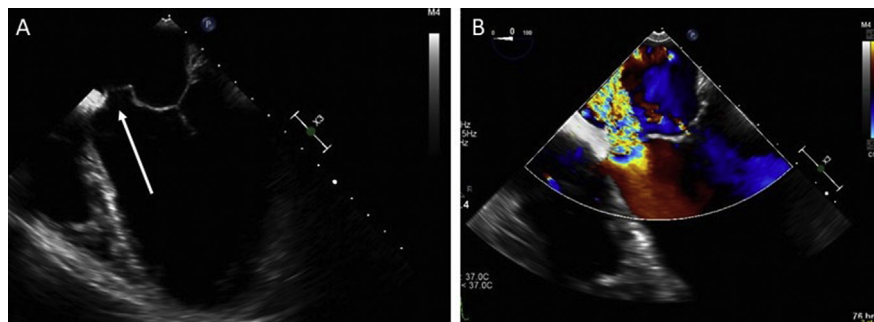


## Keywords:

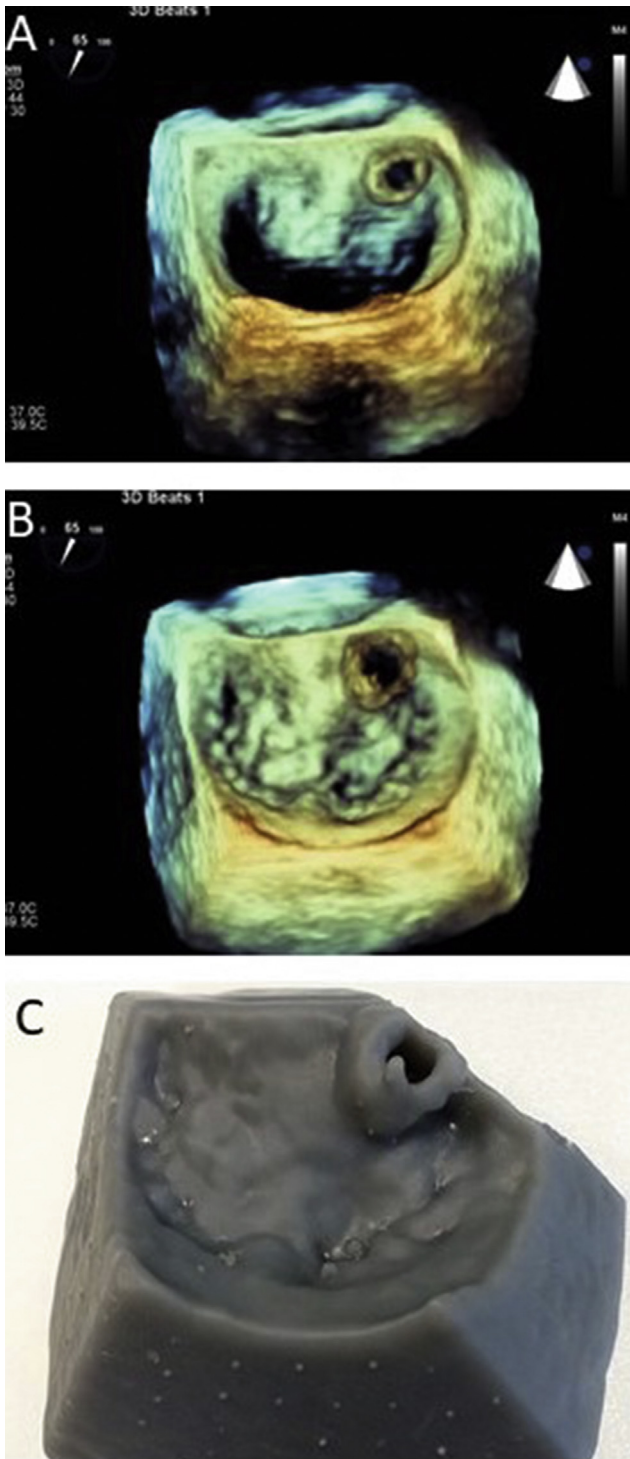
valve perforation  
transoesophageal echocardiography  
3D printing

We present a case of a 37-year-old man with a history of infective endocarditis, complicated with cerebral septic emboli, requiring an emergency aortic valve replacement (AVR) with a mechanical bileaflet prosthesis. He had a prolonged postoperative stay in intensive care unit for neurosurgical management of a cerebral abscess. A transthoracic echocardiogram (TTE) 10 days post-operatively, showed normal left ventricular (LV) systolic function, well-seated and well-functioning mechanical aortic valve prosthesis and a new jet of mild to moderate mitral regurgitation (MR) of unclear aetiology. An iatrogenic anterior mitral leaflet perforation during surgery was presumed. The patient was discharged, and the following two years had serial follow up TTEs, which showed gradual worsening of the MR to the level of severe with concomitant LV dilatation. The patient reported no cardiac symptoms, however his mobility was impaired due to right-sided

hemiparesis. There were no clinical or laboratory findings suggestive of infective endocarditis and a transesophageal echocardiogram (TEE) was performed in view of imminent surgical treatment. The TEE showed perforation of the anterior mitral leaflet (Fig. 1A - arrow; Video S1) resulting in severe MR (Fig. 1B; Video S2). The exact anatomy of the lesion was demonstrated with 3D modality, and the perforation was well identified at the base of the A3 scallop (Fig. 2A - diastole, Fig. 2B - systole; Video S3). A 3D model of the mitral valve was created with 3D printing, providing anatomical details of the lesion. Based on that, the consensus was that the perforation would not be amenable to percutaneous intervention and the surgical team used the 3D model, to better understand the anatomy and plan the surgical strategy pre-operatively, reducing the operation and cardiopulmonary bypass times (Fig. 2C). In addition to the value of 3D echocardiography<sup>1,2</sup>, it is believed that the modelling of cardiac structures with 3D printing, enhances the perception of complex anatomy and allows detailed preprocedural planning of percutaneous interventions or cardiac surgery.<sup>3</sup> The patient underwent endoscopic mitral valve repair with a pericardial patch and one year later there was no residual mitral regurgitation.



**Fig. 1.** Transesophageal echocardiogram (TEE). **A:** Mid-esophageal four chambers view, showing perforation of the anterior mitral leaflet (white arrow). **B:** Mid-esophageal four chambers view with colour flow Doppler, showing severe mitral regurgitation due to the perforation.



**Fig. 2.** **A:** TEE, 3D Zoom of the mitral valve in diastole, showing perforation of the anterior mitral leaflet (A3 scallop). **B:** TEE, 3D Zoom of the mitral valve in systole, showing the perforation. **C:** 3D model of the mitral valve created with a 3D printer. Printed models of cardiac structures can help either to explore percutaneous options of treatment with devices or to plan pre-operatively the surgical procedure.

Supplementary data related to this article can be found online at <https://doi.org/10.1016/j.hjc.2018.11.004>.

#### Disclosure

There are no conflicts of interest related to this case report for any of the authors.

#### Acknowledgements

None.

#### References

1. Patrianakos AP, Zacharaki AA, Skalidis EI, Hamilos MI, Parthenakis FI, Vardas PE. The growing role of echocardiography in interventional cardiology: The present and the future. *Hellenic J Cardiol.* 2017 Jan - Feb;58(1):17–31.
2. Rallidis LS, Makavos G, Lozos V, Antoniadis A, Paraskevaidis I, Lekakis J. Real-Time 3-Dimensional Transesophageal Echocardiography: Its Incremental Value over 2-Dimensional Echocardiography in Assessing Acute Mitral Regurgitation. *Hellenic J Cardiol.* 2015 May-Jun;56(3):260–261.
3. Bartel T, Rivard A, Jimenez A, Mestres CA, Müller S. Medical three-dimensional printing opens up new opportunities in cardiology and cardiac surgery. *Eur Heart J.* 2018 Apr 14;39(15):1246–1254.

Konstantinos C. Theodoropoulos\*, Alexandros Papachristidis, Tiago Fonseca, Joseph Reiken, Mark J. Monaghan  
 Department of Cardiology, King's College, Hospital NHS Foundation Trust, London, UK

\* Corresponding author. Department of Cardiology, King's College Hospital NHS Foundation Trust, Denmark Hill, SE5 9RS, London, United Kingdom., Fax: +442032991745, Tel: +44 7453880850.  
 E-mail addresses: [konstantinos.theodoropoulos@nhs.net](mailto:konstantinos.theodoropoulos@nhs.net), [ktheod2005@hotmail.com](mailto:ktheod2005@hotmail.com) (K.C. Theodoropoulos), [alexandros.papachristidis@nhs.net](mailto:alexandros.papachristidis@nhs.net) (A. Papachristidis), [tfonseca@nhs.net](mailto:tfonseca@nhs.net) (T. Fonseca), [velocity1966@hotmail.com](mailto:velocity1966@hotmail.com) (J. Reiken), [mark.monaghan@nhs.net](mailto:mark.monaghan@nhs.net) (M.J. Monaghan).

19 September 2018  
 Available online 15 November 2018