



King's Research Portal

Document Version
Peer reviewed version

[Link to publication record in King's Research Portal](#)

Citation for published version (APA):

López, J. D., Araúxo, A., & Paramo, M. (2009). Late-onset bipolar disorder following right thalamic injury. *ACTAS ESPAÑOLAS DE PSIQUIATRÍA*, 37(4), 233-235.

Citing this paper

Please note that where the full-text provided on King's Research Portal is the Author Accepted Manuscript or Post-Print version this may differ from the final Published version. If citing, it is advised that you check and use the publisher's definitive version for pagination, volume/issue, and date of publication details. And where the final published version is provided on the Research Portal, if citing you are again advised to check the publisher's website for any subsequent corrections.

General rights

Copyright and moral rights for the publications made accessible in the Research Portal are retained by the authors and/or other copyright owners and it is a condition of accessing publications that users recognize and abide by the legal requirements associated with these rights.

- Users may download and print one copy of any publication from the Research Portal for the purpose of private study or research.
- You may not further distribute the material or use it for any profit-making activity or commercial gain
- You may freely distribute the URL identifying the publication in the Research Portal

Take down policy

If you believe that this document breaches copyright please contact librarypure@kcl.ac.uk providing details, and we will remove access to the work immediately and investigate your claim.

J. D. López
A. Araújo
M. Páramo

Late-onset bipolar disorder following right thalamic injury

Psychiatry Department
Complejo Hospitalario Universitario de
Santiago de Compostela
Santiago de Compostela (Spain)

Bipolar disorder occurs in the elderly ages and is frequently associated to a brain injury -cerebrovascular disease. Its diagnosis is based on the finding of an ischemic injury in specific regions of the brain. The case of a 63-year-old male with cardiovascular risk factors, who was admitted due to maniform picture during a two-year long bipolar affective syndrome is presented. The neuroimaging tests showed lacunar infarction in the right thalamus and diffuse foci of ischemia in subcortical white matter having right predominance. Due to the refractoriness to psychodrugs of an endogenomorphic depressive episode, electroconvulsive therapy was prescribed, with normalization of motor component, although without mood stabilization. The therapeutic strategies and the evolution of this form of bipolarity are discussed.

Key words:

Late-onset bipolar disorder. Cerebrovascular disease. Photon emission tomography. Maintenance electroconvulsive therapy.

Actas Esp Psiquiatr 2009;37(4):233-235

Trastorno bipolar de inicio tardío secundario a lesión talámica derecha

El trastorno bipolar se presenta en edades avanzadas frecuentemente asociado a una lesión cerebral -enfermedad cerebrovascular-, y su diagnóstico se fundamenta en el hallazgo de un daño isquémico en regiones específicas del cerebro. Se presenta un varón de 63 años, con factores de riesgo cardiovascular, que ingresa por cuadro maniforme en el curso de un síndrome afectivo bipolar de 2 años de evolución. Las pruebas de neuroimagen mostraron infarto lacunar en tálamo derecho y focos difusos de isquemia en sustancia blanca subcortical de

predominio derecho. La refractariedad a psicofármacos de un episodio depresivo endógenomorfo indicó terapia electroconvulsiva, con normalización del componente motor, aunque sin eutimización. Se discuten las estrategias terapéuticas y la evolución de esta forma de bipolaridad.

Palabras clave:

Trastorno bipolar de inicio tardío. Enfermedad cerebrovascular. Tomografía de emisión de fotones. Terapia electroconvulsiva de mantenimiento.

INTRODUCTION

In 1899, E. Kraepelin presented his dichotomous classification of endogenous psychoses,¹ *Manic-Depressive Psychosis and Dementia Praecox*. His own clinical observation and the epidemiological studies verified the onset of these disorders in the second decade of life. Subsequent identification of subjects who had late-onset of clinical pictures similar to the Manic-Depressive Psychosis, the current Bipolar Disorder (BD), has been associated with the existence of a brain lesion,² the cerebrovascular disease (CVD) being one of the main causes,³ with the involvement of the injury in certain brain regions in the pathophysiology of these disorders.⁴⁻⁸

The frequent refractoriness to psychodrugs and appearance of side effects and interactions -patients with elevated medical comorbidity rates and who are polymedicated,⁸ make electroconvulsive therapy (ECT) a solid alternative⁸⁻¹⁰ for both the acute phases as well as for chronic treatment where maintenance ECT may be used.⁹

CLINICAL CASE

The case of a 63-year-old hypertensive male suffering chronic renal failure, with no personal or family psychiatric background, is presented. At 61 years, he had his first endogenous depressive episode, which responded to venlafaxine

Correspondence:

Javier David López Morínigo
Psychiatry Department
Complejo Hospitalario Universitario de Santiago de Compostela
Travesía da Choupana s/n
15706 Santiago de Compostela (Spain)
E-mail: javierlmorinigo@yahoo.es

150 mg/day, and sudden turn at five months to a maniform picture which was treated with risperidone 6 mg/day. He was stable with risperidone 0.5 mg/day. Several episodes of orthopnea and insomnia led to the diagnosis of atrial fibrillation, with pacemaker implantation. Two months later, a second melancholic episode was resolved with venlafaxine 300 mg/day. Coinciding with spring, he had a new manic episode that required an urgent admission. The brain computed tomography (CT) showed images consistent with lacunar infarction in the right thalamus and lesions in the subcortical and periventricular white matter of probable vascular origin. The brain photon emission tomography (SPECT) (figure 1) showed irregularities in the bilateral diffuse perfusion, with hypoperfusion in the inferior *gyrus temporalis*, most superior right frontal and right thalamic regions. The echo-Doppler of the supraortic trunks showed moderate stenosis in both internal carotids. Within a few days of treatment with risperidone 3 mg/day, he experienced a sudden mood change to endogenomorphic depression that was refractory to venlafaxine 300 mg/day and maprotyline 150 mg/day, which evolved to *melancholic stupor*. The motor component responded to 14 sessions of bilateral ECT with partial emotional improvement, without *restitutio ad integrum*. Sodium valproate 600 mg/day and nortriptyline 100 mg/day were introduced and four more sessions of ECT were administered prior to discharge. The score obtained on the Mini-Mental State Examination¹¹ was 23/30. He was re-admitted at 10 days due to maniform picture that was treated with quetiapine 1,200 mg/day and sodium valproate 600 mg/day. He had a new depressive episode at four months where he was treated as an out-patient

with venlafaxine 150 mg/day, with the appearance of a toxicoderma secondary to valproate two months later. He has been compensated since then with venlafaxine 150 mg/day, quetiapine 900 mg/day and oxcarbazepine 900 mg/day.

DISCUSSION

The diagnosis of BD in advanced ages makes it necessary to rule out a brain lesion. Given the cardiovascular background and findings in keeping with the structural and functional neuroimaging, it was concluded that there was a cerebrovascular ischemic origin of the picture, in which the location of the lesions in the right thalamus and subcortical white matter with predominance in the right hemisphere stood out. Its significance in the pathophysiology of affective disorders secondary to CVD has already been described.⁴⁻⁶

This case makes it possible to contemplate the maintenance therapy plan in this group of elderly bipolar patients who have frequent multiple medical conditions. These conditions make it difficult to introduce effective and well-tolerated drugs because of: a) the contraindication for lithium salts due to renal failure; b) the appearance of toxicoderma secondary to valproate. This makes it necessary to discontinue this mood stabilizer and thus leads to the use of oxcarbazepine that is less effective and entails the risk of precipitating a hyponatremia given the backgrounds of renal failure and c) the refractoriness associated to cerebrovascular origin of the picture,¹² with difficulties for mood stabilization and rapid changes of phase. Given the above, the favorable response to ECT of one of the episodes, although partial, with no medical complications or secondary cognitive deterioration has led us to consider the inclusion of these patients in a maintenance ECT program as an alternative.^{12, 13}

This case supports the existence of late-onset bipolar disorder with cerebrovascular etiology, whose therapeutic approach is a current challenge.

REFERENCES

1. E. Kraepelin. *Kompendium der Psychiatriae* (6ª ed.). Leipzig: Abel; 1899.
2. E Vieta. Trastornos bipolares y esquizoafectivos. In: J. Vallejo Ruiloba. Introducción a la Psicopatología y la Psiquiatría. Barcelona: Masson; 2006. p. 513-39.
3. Ramos-Ríos R, Berdullas Barreiro J, Varela-Casal P, Araúxo Vilar A. Depresión vascular con síntomas melancólicos: respuesta a terapia electroconvulsiva. *Actas Esp Psiquiatr* 2007;35(6):403-5.
4. Cummings JL, Mendez MF. Secondary mania with focal cerebrovascular lesions. *Am J Psychiatry* 1984;141(9):1084-7.
5. Starkstein SE, Robinson RG. Affective disorders and cerebral vascular disease. *Br J Psychiatry* 1989;154:170-82.
6. Starkstein SE, HS Mayberg, ML Berthier et al. Mania after Brain Injury: Neuroradiological and Metabolic Findings. *Ann Neurol* 1990;27:652-9.

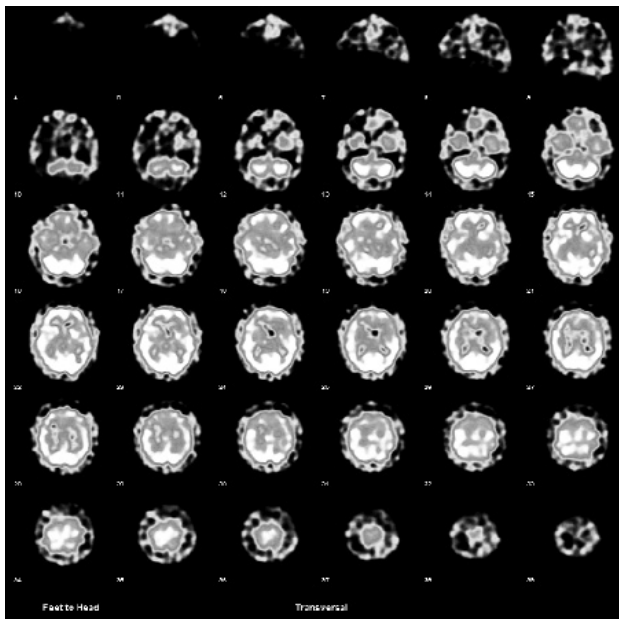


Figure 1 99m-Tc ECD BRAIN perfusion SPECT: in the slices 17-20, infarction in the right thalamus is observed while in slices 22-27, a marked hypoperfusion in the left temporal regions (see asymmetry) can be observed.

7. Berthier ML, Kulisevsky J, Gironell A, Fernández Benitez JA. Poststroke bipolar affective disorder: clinical subtypes, concurrent movement disorders, and anatomical correlates. *J Neuropsychiatry Clin Neurosci* 1996;8(2):160-7.
8. Shulman KI, Herrmann N. The nature and management of mania in old age. *Psychiatr Clin North Am* 1999;22(3):649-65.
9. Valenti M, Benabarre A, Bernardo M, García-Amador M, Amann B, Vieta E. La terapia electroconvulsiva en el tratamiento de la depresión bipolar. *Actas Esp Psiquiatr* 2007;35(3):199-207.
10. Aziz R, Lorberg B, Tampi RR. Treatments for late-life bipolar disorder. *Am J Geriatr Pharmacother* 2006;4(4):347-64.
11. Lobo A, Esquerra J, Gómez Burgada F, Sala JM, Seva A. El Mini-Examen Cognoscitivo: un test sencillo y práctico para detectar alteraciones intelectuales en pacientes médicos. *Actas Luso Esp Neurol Psiquiatr* 1979;3:189-202.
12. Sienaert P, Peuskens J. Electroconvulsive therapy: an effective therapy of medication-resistant bipolar disorder. *Bipolar Disorders* 2006;8:304-6.
13. Nascimento AL, Appolinario JC, Segenreich D, Cavalcanti MT, Brasil MAA. Maintenance electroconvulsive therapy for recurrent refractory mania. *Bipolar Disorders* 2006;8:301-3.